

Using Infrared Thermography to Detect Corneal and Extremity Temperatures of Healthy Horses

Yanmaz, L.E.* and Okumus, Z.

Department of Surgery, Faculty of Veterinary Medicine, Atatürk University, Erzurum 25240, Turkey.

* Corresponding author: Yanmaz Latif Emrah, Tel: +904422315559, Fax: +904422360881. Email: latifemrahyanmaz@gmail.com.

ABSTRACT

The infrared thermal camera is a sensitive and non-invasive tool for detecting temperature changes. In this experiment, the temperature of the cornea and extremities were measured in 25 healthy horses ranging from 3 to 21 years old (19 Arabian, 6 Thoroughbred; 6 female and 19 male; 11 chestnut, 6 bay, 8 gray; 6 stallion, 19 sporting) to determine effects of breed, coat color, and rearing purposes using infrared thermography. Data were analyzed by using Student's *t*-test and Tukey's range test. There was no difference in cornea temperature due to breed, skin coat color and rearing purpose; the mean corneal temperature was 32.58 ± 0.13 °C. There were no breed differences in extremity regions' skin surfaces. Forelimb coronary corium temperature in gray horses (30.79 ± 0.51 °C) was lower than that for bay (32.20 ± 0.49 °C) and chestnut (32.09 ± 0.18 °C) horses. Sporting horses had 1-2 °C higher coronary corium, heel bulb, metacarpal, sesamoid bone temperatures than stallions. It was concluded that the extremity skin surface temperature was higher in sporting horses and lower in gray horses, possibly due to increased blood flow.

Keywords: Infrared thermography, Extremity, Cornea, Coat color, Horse.

INTRODUCTION

Thermography is a non-invasive diagnostic imaging technique used to detect variations in body surface temperature by measuring emitted infrared radiation (1). Over the past few years, diagnostic thermography has provided the clinician with accurate, non-invasive and reliable means of evaluating equine musculoskeletal disorders and the early diagnosis of suspect severe orthopedic injuries (2).

Research using thermography in horses has mainly focused on laminitis, navicular syndrome, arthritis, tendinitis and back pain problems associated with thoracolumbar lesions (3-6). Using thermography in all these orthopedic problems is based on blood flow alterations resulting in surface heat emitted from injured tissue (7).

Recently there have been much research concerning measurements of corneal temperature as an index of core body temperature, such as being used in the diagnosis of bovine viral diarrhea (8), bovine respiratory disease (9), and stress

measurements (10). Johnson *et al.* identified that thermography could be used to determine fever in ponies (11). Other researches focused on detecting skin surface temperature to predict pregnancy (12) and adaptation to environmental conditions (13).

However, there is a dearth in the literature concerning breed, coat color and rearing purpose to evaluate the regional temperatures of extremities, and corneal temperature. The purpose of the study reported here was to detect corneal and the extremity region temperature alterations in healthy horses for different breed, coat color and rearing purpose.

MATERIALS AND METHODS

Twenty five healthy horses ranging in age from 3 to 21 years old (19 Arabian, 6 Thoroughbred; 6 female and 19 male; 11 chestnut, 6 bay, 8 gray; 6 stallion, 19 sporting) were used in this study. The horses were admitted to the Turkish Jockey Club Sanliurfa Racecourse hospital, during the pe-

riod February 2011 to March 2011. The experimental protocol was approved by the Atatürk University Health Science Institution. After the physical examination of eyes, fore- and hindlimbs, horses that did not have ocular clinical signs and lameness or musculoskeletal injury were housed in indoor 12x12 foot, stalls.

To minimize interferences of light, air flow and to adapt the horses to the similar conditions, thermographic examination were carried out in a room without direct sunlight. Relative humidity and ambient temperatures were recorded before each horse was accepted to the examination room and these values entered into the camera calibration. After horses had rested 15 min in the room, the thermal camera (IR FlexCam S, Infrared Solutions Inc., Plymouth, MN, USA) was placed at a 1 meter distance from the examined region.

Thermographic extremity examinations included fore- and hindlimb fetlocks (dorsal, lateral and medial views), right and left carpus/tarsus (dorsal, lateral, palmar and medial views), right and left metacarpus/tarsus (dorsal, lateral and medial views), right and left flexor tendons (palmar/plantar views), right and left coronary bands (dorsal views), right and left navicular bones (lateral and medial views), right and left heel bulbs. All corneal temperatures were measured from the center of the right and left cornea (Figure 1).

STATISTICS

All data in the study was evaluated using Statistical Analysis System (SAS Institute Inc., Cary, NC, USA). Prior to assessment of temperatures (cornea and different parts of ex-

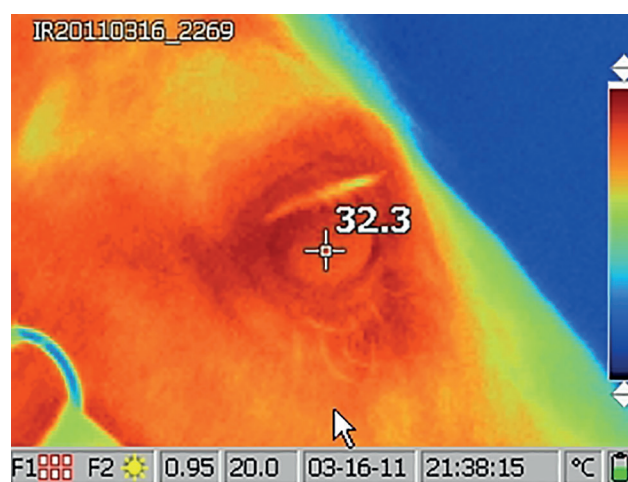


Figure 1

tremity regions), horses were divided into subgroups according to breed, coat color and rearing purpose. The differences between these groups were evaluated by using the Student's t-test. For multiple comparisons, Tukey-Kramer adjustment was used. In all measurements, statistical significance was set at $p < 0.05$. Data were presented as mean \pm SE.

RESULTS

There was no difference in corneal temperatures due to breed, skin coat color and rearing purpose; the mean corneal temperature was 32.58 ± 0.13 °C. Skin surface temperature varied by the extremity region. The highest temperature was measured in the heel bulb (32.18 ± 0.38 °C), followed by the coronary corium (31.18 ± 0.28 °C). In other regions including carpal, metacarpal, flexor tendon, fetlock, sesamoid bone, tar-

Table 1: Effects of coat color on corneal, coronary corium and bulb of heels temperature

Parameter	Chestnut Horses (n=11)		Bay Horses (n=6)		Gray Horses (n=8)		P
	Mean \pm SE	Range	Mean \pm SE	Range	Mean \pm SE	Range	
Right cornea	32.71 \pm 0.08	32.30-33.10	32.57 \pm 0.14	32.00-33.00	32.35 \pm 0.36	30.50-33.80	0.479
Left cornea	32.52 \pm 0.09	32.10-32.90	32.70 \pm 0.10	32.40-33.00	32.64 \pm 0.24	31.40-33.80	0.706
Forelimb right coronary corium	32.09 \pm 0.18	31.10-33.00	32.20 \pm 0.49	30.80-34.10	30.79 \pm 0.51	28.90-32.70	0.026
Forelimb left coronary corium	32.17 \pm 0.31	30.60-34.30	32.13 \pm 0.29	31.30-32.90	31.04 \pm 0.39	29.80-32.60	0.046
Forelimb right bulb of heels	32.07 \pm 0.41	29.00-34.00	32.73 \pm 0.64	29.70-33.90	31.90 \pm 0.62	29.30-34.00	0.585
Forelimb left bulb of heels	32.18 \pm 0.48	28.20-34.70	32.67 \pm 0.44	30.50-33.30	31.81 \pm 0.48	30.10-34.20	0.546

Table 2: Effects of rearing purpose on corneal, coronary corium and bulb of heels temperature

Parameter	Sport Horses (n=19)		Stallions (n=6)		P
	Mean±SE	Range	Mean±SE	Range	
Right cornea	32.63 ±0.15	30.50-33.80	32.33 ±0.15	31.90-33.00	0.314
Left cornea	32.61 ±0.11	31.40-33.80	32.57 ±0.14	32.20-33.10	0.836
Forelimb right coronary corium	32.00 ±0.26	29.20-34.10	30.75 ±0.41	28.90-31.80	0.023
Forelimb left coronary corium	32.07 ±0.24	29.80-34.30	30.95 ±0.32	29.90-32.30	0.024
Forelimb right bulb of heels	32.57 ±0.29	29.70-34.00	30.93 ±0.66	29.00-32.60	0.016
Forelimb right bulb of heels	32.59 ±0.24	30.50-34.70	30.87 ±0.69	28.20-33.10	0.005

sal, and metatarsal temperatures ranged from 23.62 to 29.31 °C. All measurements were made on forelimbs, anterior parts, and medial parts were 1 °C greater than those made in hind limbs, posterior parts, and lateral parts, respectively. There were no breed differences in extremity regions' skin surface temperatures. Forelimb coronary corium temperature in gray horses (30.79±0.51 °C) was lower than that for bay (32.20±0.49 °C) and chestnut (32.09±0.18 °C) horses. Effects of coat color on corneal, coronary corium and bulb of heels temperature were shown in Table 1. Hind coronary corium temperature did not differ by skin coat color. Sporting horses had 1-2 °C higher coronary corium, heel bulb, metacarpal, sesamoid bone temperatures than stallions. Effects of rearing purpose on corneal, coronary corium and bulb of heels temperature were shown in Table 2.

DISCUSSION

The major advantages of using thermography in equine medicine are detection of lameness and help preventing serious injuries. When thermography is used in the diagnosis of orthopedic problems, generally, comparisons between the symmetrical limbs are used, because thermographically determined surface temperature patterns in horses have a high degree of bilateral symmetry between the thoracic limbs distal to carpus and the pelvic limbs distal to the tarsus (14-15). Comparison of symmetric regions is able to give clues about the existence of inflammation and in this way help the clinician make an accurate diagnosis. However, in bilateral orthopedic problems, thermographic examinations for the evaluation of inflammation may lead to false results. For this

purpose, in thermographic applications, determining reference values for extremities may provide a significant advantage to the clinician for diagnosis of orthopedic conditions and the detection of inflammation.

It is apparent that many of the lameness conditions in horses occur distal to the carpus and tarsus. When evaluating lameness with the thermographic examination, it is obvious that the fore- and hindlimb should be examined from two directions and if there is suspicion such as hot spot it should be checked at least from four directions approximately 90° apart (1, 6). In this study, the thermal images of fore- and hindlimbs conducted from four directions which is in the more accurate examination.

Measuring corneal temperatures to detect body core temperature provided some advantages, such as protection of the clinician from injury and gave an alternative method to time-consuming procedures for detection of the body temperature by rectal thermometer (16). Johnson *et al.* found that mean eye temperatures of horses was 38.2 °C. However, in the current study measured mean corneal temperature was 32.6 °C. This discrepancy is probably due to measurements of different parts of the eye. Johnson *et al.* measured the eye temperatures from the caruncula lacrimalis the region which is rich in blood vessels, however in our study we measured from the center of the cornea.

When evaluating the horses by using infrared thermal camera, it may be beneficial to consider not only external factors (ambient temperature, acclimatization, light and air flow), but also patient-related factors (breed, coat color and rearing purpose). Jodkowska and Dudek identified that

training caused a significant increase of body surface temperature, higher in mares than in the stallions. The increase of forelimb temperatures was higher than in hindlimbs after training sessions (18). In this research, we found that there were no breed differences in extremity regions' skin surface temperatures. However, sporting horses had about 1-2 °C higher coronary corium, heel bulb, metacarpal, sesamoid bone temperatures than stallions which had similar results to those of Jodkowska and Dudek (18).

Although thermography should be performed when the hair is short and uniform (1), there is no information concerning the coat color effect on the thermographic temperatures. Lustick 1971, and Maloney *et al.* have generally accepted that dark coats absorb more solar radiation than light coats which can have an effect on the body temperature (19, 20).

In this study, contrary to expectations there were not any temperature differences between coat color and extremity regions, except for forelimb coronary corium. Forelimb coronary corium temperature in gray horses (30.79±0.51 °C) was lower than that for bay (32.20±0.49 °C) and chestnut (32.09±0.18 °C) horses. This discrepancy could be related to the increased blood flow or interference in thermal conductance by hair or other internal and external factors (6).

In conclusion, when evaluating the temperatures of extremities, rearing purpose and coat color of animals should be considered before establishing the study plan of an experiment. Moreover, we suggest that further research should be focused on how the coat color and rearing purpose effect body temperature.

REFERENCES

1. Turner, T.A.: Diagnostic thermography. *Vet. Clin. N. Am-Equine.* 17:95-113, 2001.
2. Eddy, A.L., Van Hoogmoed, L.M. and Snyder, J.R.: The role of thermography in the management of equine lameness. *Vet. J.* 162:172-181, 2001.
3. Fonseca, B.P.A., Alves, A.L.G., Nicoletti, J.L.M., Thornassian, A., Hussni, C. and Mikail, S.: Thermography and ultrasonography in back pain diagnosis of equine athletes. *J. Equine Vet. Sci.* 26:507-516, 2006.
4. Head, M.J. and Dyson, S.: Talking the temperature of equine thermography. *Vet. J.* 162:166-167, 2001.
5. Turner, T.A.: Thermography. From the Proceedings 1996 Dubai Symposium. 1-14, 1996.
6. Yanmaz, L.E., Okumus, Z. and Dogan, E.: Instrumentation of thermography and its applications in horses. *J. Anim. Vet. Adv.* 6:858-862, 2007.
7. Katsberger, G. and Stachl, R.: Infrared imaging technology and biological applications. *Behav. Res. Methods Instrum. Comput.* 35:429-439, 2003.
8. Schaefer, A.L., Cook, N., Tessaro, S.V., Deregt, D., Desroches, G. and Dubske, P.L.: Early detection and prediction of infection using infrared thermography. *Can. J. Anim. Sci.* 84:73-80, 2004.
9. Schaefer, A.L., Cook, N.J., Church, J.S., Basarab, J., Perry, B. and Miller, C.: The use of infrared thermography as an early indicator of bovine respiratory disease complex in calves. *Res. Vet. Sci.* 83:376-84, 2007.
10. Stewart, M., Schaefer, A., Hale, D.B., Colyn, J., Cook, N.J., Stafford, K.J. and Webster, J.R.: Infrared thermography as a non-invasive method for detecting fear-related responses of cattle to handling procedures. *Anim. Welfare.* 17:387-393, 2008.
11. Johnson, S.R., Rao, S., Hussey, S.B., Morley, P.S. and Traub-Dargatz, J.L.: Thermographic eye temperature as an index to body temperature in ponies. *J. Equine Vet. Sci.* 31:63-66, 2011.
12. Bowers, S., Gandy, S., Anderson, B., Ryan, P. and Willard, S.: Assessment of pregnancy in the late-gestation mare using digital infrared thermography. *Theriogenology.* 72: 372-377, 2009.
13. Kotrba, R., Knizkova, I., Kunc, P. and Bartos, L.: Comparison between the coat temperature of the eland and dairy cattle by infrared thermography. *J. Therm. Biol.* 32: 355-359, 2007.
14. Turner, T.A.: Thermography as an aid to the clinical lameness evaluation. *Vet. Clin. N. Am-Equine.* 7:311-338, 1991.
15. Simon, E.L., Gaughan, E.M., Epp, T. and Spire, M.: Influence of exercise on thermographically determined surface temperatures of thoracic and pelvic limbs in horses. *J. Anim. Vet. Adv.* 229:1940-1944, 2006.
16. Ramey, D., Bachmann, K. and Lee, L.M.: A comparative study of non-contact infrared and digital rectal thermometer measurements of body temperature in the horse. *J. Equine Vet. Sci.* 31:191-193, 2011.
17. Johnson, S.R., Rao, S., Hussey, S.B., Morley, P.S. and Traub-Dargatz, J.L.: Thermographic eye temperature as an index to body temperature in ponies. *J. Equine Vet. Sci.* 31: 63-66, 2011.
18. Jodkowska, E. and Dudek, K.: Significance of body surface temperature measurements in exploitation of horses. *Medycyna. Wet.* 59:584-587, 2003.
19. Lustick, S.: Plumage color and energetics. *Condor.* 73:121-222, 1971.
20. Maloney, S.K., Fuller, A. and Mitchell, D.: Climate change: is the dark Soay sheep endangered? *Biol. Letters.* 5:826-829, 2009.