

# Case Report: Cardiac Auricular Hemangiosarcoma Resection in a Dog

Merhavi, N., Atamna, R., Peery, D., Ohad, D.G. and Yudelevitch, S.

The Hebrew University, Koret School of Veterinary Medicine – Veterinary Teaching Hospital, Rehovot, 76100, Israel.

\* **Corresponding author:** Dr. Nadav Merhavi, D.V.M.; Email : nadavet26@gmail.com; Phone: +972-3-9688588

## ABSTRACT

This case report describes the challenging diagnosis and treatment of a dog diagnosed with cardiac auricular hemangiosarcoma. The dog was presented to the emergency department at the Hebrew University Veterinary Teaching Hospital in lateral recumbency and was diagnosed with pericardial sac effusion and cardiac tamponade due to a right cardiac auricular mass. As repeated pericardial drainage did not resolve the continuous effusion and cardiac tamponade, the dog was treated surgically and the mass was removed. The dog returned 4 months after surgery due to collapse and was diagnosed with hemothorax. The owners reported that the dog died at home 127 days after surgery.

---

**Keywords:** Hemangiosarcoma; Pericardectomy; Tamponade; Canine.

## INTRODUCTION

Cardiac tumors are considered uncommon in dogs (1,2). The most common cardiac tumor is hemangiosarcoma (HSA), although aortic body tumors (chemodectoma), lymphoma and ectopic thyroid carcinoma have also been described (2). Cardiac tumors may be malignant or benign, primary or secondary. In most cases, primary cardiac HSA (CHSA) is located in or attached to the right atrium or right atrial auricle (2,3), however, it may appear as a diffuse infiltrative tumor as well (2). There appears to be a higher incidence of CHSA in German Shepherd and Golden Retriever dogs with no apparent sex predilection (3). One paper described an increased risk for CHSA in spayed female dogs compared to intact females (4).

Presenting signs of CHSA are usually related to pericardial effusion, cardiac tamponade and signs of congestive right and/or forward left sided heart failure, including ascites, lethargy, pallor, collapse, exercise intolerance and dyspnea (3,5,6). Echocardiography is the imaging modality of choice for detection of cardiac tumors in dogs. Computed tomography (CT) may be useful in evaluating a suspected mass where echocardiography is inconclusive, determining the origin of

the mass and whether pulmonary metastases are present (7). Definitive diagnosis of cardiac tumors may be challenging as pericardial effusion cytology is usually non-diagnostic and because the mass may be inaccessible for fine needle aspiration (8). Sampling of cardiac masses is not a routine procedure, mainly given the potential risk for arrhythmia and hemorrhage (2). However, one study found that ultrasound guided fine needle aspiration obtained from cardiac tumors was very likely to be diagnostic and result in only minor complications (1). By the time of diagnosis, CHSA has usually metastasized and should be considered a systemic disease (9,10). The longest median survival times (MST) have been achieved with a combination of surgical resection and chemotherapy (11).

This case report describes the diagnosis and challenging treatment of a right auricular CHSA in a 7-year-old castrated Dogue de Bordeaux dog. Extensive diagnosis included echocardiography by a board certified cardiologist, thoracic CT, ultrasound guided aspiration from the mass and histopathology of the mass following resection. Palliative treatment included pericardectomy and atrial mass resection, enabling the dog to survive 127 days post-surgery with an excellent quality of life.

## CASE REPORT

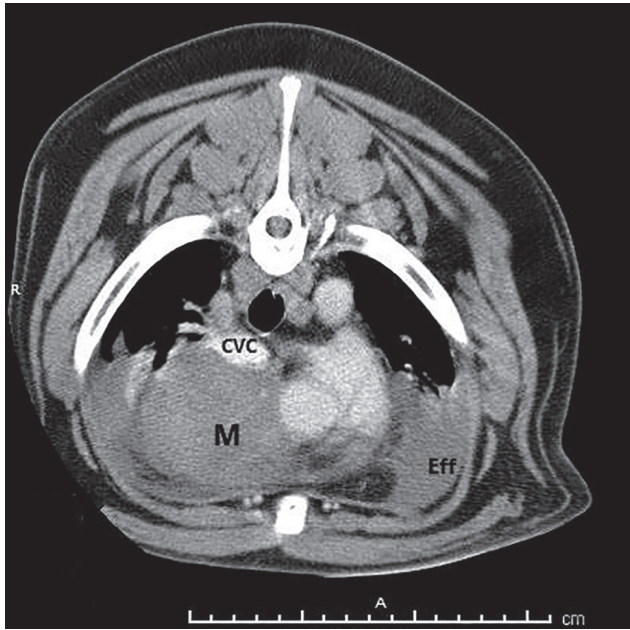
The aforementioned dog was presented to the emergency department at the Veterinary Teaching Hospital of the Koret School of Veterinary Medicine, Hebrew University of Jerusalem, due to two days duration of apathy and anorexia. Physical examination findings were lateral recumbency, 8% dehydration, sinus tachycardia (156 beats per minute; Reference Interval [RI] 70-120 beats per minute), normal rectal temperature (38.4°C; RI 38-39.2°C) and panting (RI 18-34 breaths per minute) with an abdominal effort. Thoracic auscultation detected muffled heart sounds. Mucous membranes were pale and dry. Thoracic and abdominal Focused Assessment with Sonography in Trauma (FAST) demonstrated a large amount of peritoneal effusion, pericardial effusion and cardiac tamponade. A venous catheter was placed and one liter of 0.9% saline (Teva Pharmaceuticals Industries Ltd, Petah-Tikva, Israel) was administered as an intravenous bolus. The dog was sedated with intravenous Diazepam (Assival Teva, Teva Pharmaceuticals Industries Ltd, Petah-Tikva, Israel, 0.1 mg/kg, intravenously) and 250 ml of hemorrhagic effusion were drained from the pericardial sac under ultrasound guidance. Pulse rate then slowed down to 100 beats per minute. Complete blood count detected low red blood cell count ( $5.5 \times 10^6/\mu\text{L}$ ; RI  $5.7\text{-}8.8 \times 10^6/\mu\text{L}$ ), leukocytosis ( $17.4 \times 10^3/\mu\text{L}$ ; RI  $5.2\text{-}13.9 \times 10^3/\mu\text{L}$ ), elevated RDW (15.3%; RI 11.9-14.7%), elevated MPV (14.4 fL; RI 7-11 fL) and elevated MCV (74.7 fL; RI 58.8-71.2 fL). Platelets count was within normal limits. Serum biochemistry profile detected elevated AST (65 IU/L; RI 19-42 IU/L), elevated urea (107.4 mg/dL; RI 10.7-53.5 mg/dL), elevated creatinine (1.7 mg/dL; RI 0.3-1.2 mg/dL), hypocalcemia (9.3 mg/dL; RI 9.7-11.5 mg/dL) and hypochloremia (99.2 mmol/L; RI 104-118 mmol/L). Coagulation prothrombin time and partial thromboplastin time were found to be within normal limits while fibrinogen concentration was low (167.41 mg/dL; RI 200-400 mg/dL).

Echocardiography was performed by a board certified veterinary cardiologist, demonstrating a 5.2x4.5 cm cavitated mass located between the right atrial body and appendage and the ascending aorta. Other than triggering cardiac tamponade with a resultant cardiogenic shock, the mass did not appear to be causing any cardiac dysfunction. Abdominal ultrasound detected a large amount of anechoic peritoneal effusion with no abnormalities in any abdominal organ. The

peritoneal effusion was aspirated. Fluid analysis was not performed and its accumulation was considered a result of cardiac tamponade.

The dog was admitted and the amount of effusion in the pericardial sac was monitored. Treatment included Tranexamic acid (Tranex, Bioindustrial L.I.M. S.p.A. Noviligure, Italy, 15 mg/kg, intravenously), Cefazolin (Cefazolin-Fresenius, Labesfal Laboratories Almiro, S.A, Fresenius Kabi Group, Portugal, 25 mg/kg, intravenously) and Maropitant (Cerenia, Fareva, Amboise, France, 1 mg/kg, subcutaneously). The dog was discharged the following day with no evidence of recurrent pericardial effusion but presented two weeks later due to recurrent collapse and in lateral recumbency. Hematocrit value was 41.5% (RI 37.1-57%), total solids were 6.8 mg/dL (RI 6-8 mg/dL) and serum creatinine was 2.66 mg/dL. Thoracic ultrasound detected recurrence of pericardial effusion and 50 ml of hemorrhagic effusion were aspirated from the pericardial cavity.

In order to better evaluate the size of the mass, its origin and rule out pulmonary metastases, a thoracic helical CT scan was performed (Philips, IMX-DT 8000; 120 kVp, 250 mAs, 3 mm slices). The dog was sedated with Methadone (Physeptone, Martindale Pharmaceuticals, Romford, Essex, United Kingdom, 1mg/kg, intravenously) and anesthetic induction performed with Etomidate (Etomidate-Lipuro, B.Braun Melsungen, Germany, 0.2 mg/kg, intravenously) and Diazepam (Assival Teva, Teva Pharmaceutical Industries Ltd, Petah-Tikva, Israel, 0.5 mg/kg, intravenously). The dog was intubated with a cuffed endotracheal tube and anesthesia was maintained with Isoflurane (Isoflurane, USP Terrel, Piramal Critical Care Inc, Bethlehem, Pennsylvania, USA). Large amount of pleural effusion was demonstrated bilaterally and a soft tissue attenuating mass, located between the fourth and eighth ribs, was demonstrated along the right side of the heart (Figure 1). Its diameter at the largest point was measured as 77x62mm. The mass was compressing the right ventricle and right atrial auricle, causing distention of both the cranial and caudal venae cavae. The mass was heterogeneous and non-uniformly enhanced following intravenous contrast medium administration (Omnipaque, GE Healthcare Ireland, Cork, Ireland, 600 mg/kg). Atelectasis of the ventral area of the right middle and left cranial lung lobes were noted. Sternal lymph nodes were enlarged measuring 17 x 19mm. Lung metastases were not apparent. A minimal amount of

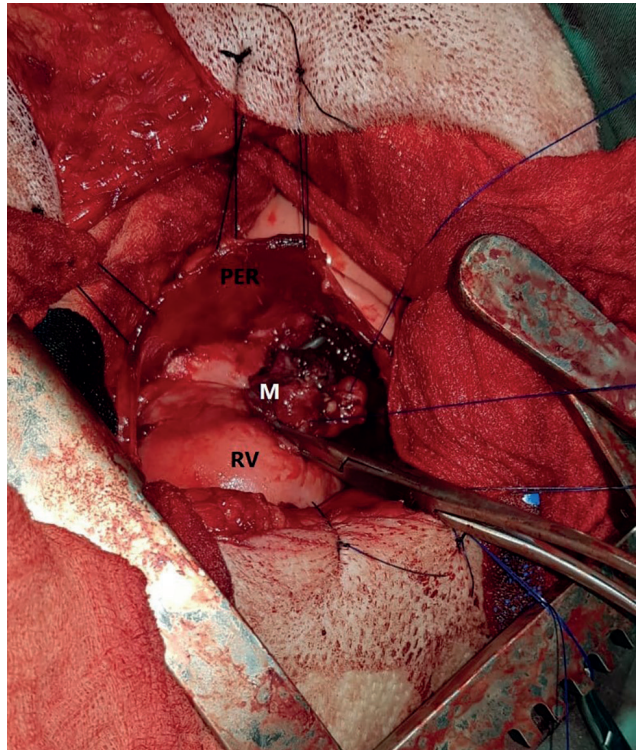


**Figure 1:** A transverse computed tomography image of the cardiac mass (soft tissue window) at the level of the fifth rib of a 7 year old Dogue de Bordeaux dog following injection of intravenous contrast medium. Bilateral pleural effusion, bilateral lung atelectasis, compression of the caudal vena cava and the cardiac mass are visible. Distension of both the cranial and caudal venae cavae is not apparent in this image. (M, Mass; Eff, Pleural Effusion; CVC, Caudal Vena Cava).

pneumothorax was demonstrated in the left hemithorax. Areas of aortic wall mineralization were detected.

Following the CT scan and while under anesthesia, ultrasound guided fine needle aspiration was performed with a 5 ml syringe and a 22-gauge needle. The samples however, were not diagnostic. Due to repeated episodes of pericardial effusion and collapse, the owners elected to pursue mass resection and pericardectomy as a palliative treatment and the dog was transferred to the operation theatre.

The dog was placed in left lateral recumbency and thoracotomy performed through the right fifth intercostal space. A controlled stab incision was performed through the pericardial sac ventral to the right phrenic nerve, allowing access to the right auricular mass. Following removal of adhesions between the pericardium and the mass, a purse string suture was placed at the base of the mass, minimizing bleeding during dissection (Figure 2). The stump was sutured with a 4-0 polypropylene simple continuous suture and a sub-total pericardectomy was then performed,



**Figure 2:** This image demonstrates the right cardiac auricular mass (M) as seen during surgery of a 7 year old Dogue de Bordeaux following reflection of the thickened pericard (PER) and placement of the purse string suture. RV, Right Ventricle.

followed by a thoracostomy tube placement in the right hemithorax.

Recovery from anesthesia was uneventful. Post-operative treatment included lactated ringer solution, Cefazolin, Fentanyl (Fentanyl-Janssen, GlaxoSmithKline Manufacturing S.p.A., Torriale, Italy, 2 µg/kg, intravenously) and Lidocaine (Esracain, Rafa Laboratories LTD, Jerusalem, Israel, 2 mg/kg, intravenously).

The mass was evaluated histologically and was composed of disorganized proliferation of atypical oval cells forming irregular blood-filled spaces, containing and surrounded by abundant hemorrhage, consistent with hemangiosarcoma. The dog was discharged 36 hours post-surgery. According to the owners, the dog recovered completely at home.

The dog was presented again 120 days post-surgery due to collapse. Abnormal physical examination findings were tachypnea and pale mucous membranes. Thoracic ultrasound detected a large amount of pleural effusion and approximately 2 liters of hemorrhagic effusion were drained. The owners elected to take the dog for additional treatment at their



veterinarian's clinic. The dog died a few days later, 127 days post-surgery. Post-mortem evaluation was not pursued.

## DISCUSSION

Hemangiosarcomas are aggressive, malignant tumors of endothelial (12) or of pluripotent bone marrow progenitor cell origin (13). Cardiac hemangiosarcoma is the most common form of cardiac neoplasia in dogs (1) and affected dogs may present with cardiac tamponade, metastatic disease, arrhythmia or heart failure (8). In dogs with CHSA, metastases typically occur early in the course of the disease and are quite common at the time of necropsy (12), most commonly found in the lungs, spleen and liver (3). In one retrospective study, nine of 31 (29%) dogs with CHSA also had a concurrent splenic mass, diagnosed post-mortem as hemangiosarcoma (14). In the present case, ultrasonography of the abdominal organs as well as thoracic CT did not detect any evidence of metastasis. Detection of metastasis, however, depends on many factors such as resolution of the ultrasound equipment, nodule size and operator experience and skill. Therefore, subtle changes in abdominal or thoracic organs may have been missed (15). As post-mortem evaluation was not performed, the presence of metastatic lesions at the time of death was not confirmed.

Studies have shown that dogs with CHSA have short median survival times of 12 days (10) or 7.1 days (3) when left untreated. One study showed that medical management (antibiotics, glucocorticoids, diuretics, antiarrhythmics and digitalis) seem to prolong MST slightly, however, some dogs were also treated with repeated pericardiocenteses, which might bias this finding (3). Pericardectomy aims to prevent further pericardial effusion and prevent cardiac tamponade, however, it may increase the risk of fatal hemorrhage. Reports of pericardectomy for dogs with presumptive CHSA do not suggest clinical benefit (11).

The applicability of atrial mass resection is restricted to a limited group of affected dogs due to several limiting factors, such as tumor size, tumor location, involvement of cardiac valves or coronary arteries and the ability to replace resected tissue (10). Complications of atrial mass resection may include pain, cardiac arrhythmias and bleeding (12,16). Controversy exists in regards to whether surgical resection of such tumors may increase MST (3) or may not change survival times compared to pericardectomy or non-surgical treatment (10, 17).

An alternative to surgery is chemotherapy, given as a monotherapy with a MST of 116 days (11), with only mild to moderate gastrointestinal toxicities and clinically silent neutropenia (10). The best reported outcome for dogs with CHSA have been achieved with a combination of surgical resection and chemotherapy (MST of 175 days) (11). The decision to pursue surgical treatment for the present case was made due to recurrent cardiac tamponade with acute collapse, allowing the dog to have a better quality of life within the short life time expectancy. The dog died 127 days post-surgery, significantly longer than described in other reports evaluating the survival times of dogs following atrial mass resection (12, 17), but within the range of another study evaluating such procedure in stage-2 CHSA affected dogs (3).

Ultrasound guided fine needle aspiration of the mass was performed in order to determine its cellular composition. Cytology may rule out lymphoma or myocarditis, which may be managed medically rather than surgically (1). The samples, however, were non-diagnostic in the present case. They were taken in an identical manner as described in another paper (1) in which all ultrasound guided aspiration from cardiac masses were diagnostic (6 dogs, 2 dogs diagnosed with CHSA). It is possible that despite Doppler guidance, the samples were taken from a blood vessel or a blood-filled cavity.

## CONCLUSION

The dog in this case report did not suffer from any complications during or after the described procedure. Surgical resection should be considered in future patients diagnosed with CHSA in which recurrent pericardiocentesis cannot be offered or is considered non-beneficial, given that owners are made fully aware of surgery being palliative rather than curative.

## REFERENCES

1. Pedro, B., Linney, C., Navarro-Cubas, X., Stephenson, H., Dukes-McEwan, J., Gelzer, A.R. and Kraus, M.S.: Cytological diagnosis of cardiac masses with ultrasound guided fine needle aspirates. *J. Vet. Cardiol.* 18:47-56, 2016.
2. Treggiari, E., Pedro, B., Dukes-McEwan, J., Gelzer A.R. and Blackwood, L.: A descriptive review of cardiac tumours in dogs and cats. *Vet. Comp. Oncol.* 15:273-288, 2015.
3. Yamamoto, S., Hoshi, K., Hirakawa, A., Chimura, S., Kobayashi, M. and Machida, N.: Epidemiological, clinical and pathological

- features of primary cardiac hemangiosarcoma in dogs: A review of 51 cases. *J. Vet. Med. Sci.* 75:1433-1441, 2013.
4. Ware, W.A. and Hopper, D.L.: Cardiac tumors in dogs: 1982-1995. *J. Vet. Intern. Med.* 13:95-103, 1999.
  5. Warman, S.M., McGregor, R., Fews, D. and Ferasin, L.: Congestive heart failure caused by intracardiac tumours in two dogs. *J. Small Anim. Pract.* 47:480-483, 2006.
  6. Osuga, T., Nakamura, K., Morita, T., Kagawa, Y., Ohta, H. and Takiguchi, M.: Diastolic heart failure associated with hemangiosarcoma infiltrating left ventricular walls in a dog. *Can. Vet. J.* 58:1167-1170, 2017.
  7. Choate, C.J. and Brinkman-Ferguson, E.: Vet Med Today – What is your diagnosis? *J. Am. Vet. Med. Assoc.* 238:1407-1408, 2011.
  8. Rajagopalan, V., Jesty, S.A., Craig, L.E. and Gompf, R.: Comparison of presumptive echocardiographic and definitive diagnoses of cardiac tumors in dogs. *J. Vet. Intern. Med.* 27:1092-1096, 2013.
  9. Johnson, V., Hansson, K., Mai, W., Dukes-McEwan, J., Lester, N., Schwarz, T., Chapman, P. and Morandi, F.: The heart and major vessels. In: Schwarz, T and Johnson, V. (Eds): *BSAVA Manual of Canine and Feline Thoracic Imaging*. British Small Animal Veterinary Association. Gloucester, pp. 86-176, 2008.
  10. Mullin, C.M., Arkans, M.A., Sammarco, C.D., Vail, D.M., Britton, B.M., Vickery, K.R., Risbon, R.E., Lachowicz, J., Burgess, K.E., Manley, C.A. and Clifford, C.A.: Doxorubicin chemotherapy for presumptive cardiac hemangiosarcoma in dogs. *Vet. Comp. Oncol.* 14:e171-e183, 2014.
  11. Nolan, M.W., Arkans, M.M., LaVine, D., DeFrancesco, T., Myers, J.A., Griffith, E.H., Posner, L.P., Keene, B.W., Tou, S.P. and Gieger, T.L.: Pilot study to determine the feasibility of radiation therapy for dogs with right atrial masses and hemorrhagic pericardial effusion. *J. Vet. Cardiol.* 19:132-143, 2017.
  12. Weisse, C., Soares, N., Beal, M.W., Steffey, M.A., Drobatz, K.J. and Henry, C.J.: Survival times in dogs with right atrial hemangiosarcoma treated by means of surgical resection with or without adjuvant chemotherapy: 23 cases (1986-2000). *J. Am. Vet. Med. Assoc.* 226:575-579, 2005.
  13. Kim, J.H., Graef, A.J., Dickerson, E.B. and Modiano, J.F.: Pathobiology of hemangiosarcoma in dogs: Research advanced and future perspectives. *Vet. Sci.* 2:388-405, 2015.
  14. Boston, S.E., Higginson, G. and Monteith G.: Concurrent splenic and right atrial mass at presentation in dogs with HSA: A retrospective study. *J. Am. Anim. Hosp. Assoc.* 47:336-341, 2011.
  15. O'Brien, R.T.: Improved detection of metastatic hepatic hemangiosarcoma nodules with contrast ultrasound in three dogs. *Vet. Radiol. Ultrasound.* 48:146-148, 2007.
  16. Crumbaker, D.M., Rooney, M.B. and Case, J.B.: Thoracoscopic subtotal pericardectomy and right atrial mass resection in a dog. *J. Am. Vet. Med. Assoc.* 237:551-554, 2010.
  17. Morges, M., Worley, D.R., Withrow, S.J. and Monnet, E.: Pericardial free patch grafting as a rescue technique in surgical management of right atrial HSA. *J. Am. Anim. Hosp. Assoc.* 47:224-228, 2011.