

WHAT IS YOUR DIAGNOSIS?

Sontas, B.H¹., Dokuzeylül, B²., Turna, Ö¹., Sarun, S³. and Ekici, H¹.

¹Department of Obstetrics and Gynaecology, ²Department of Internal Medicine, ³Department of Pathology, Faculty of Veterinary Medicine, Istanbul University, Avcilar Campus, Avcilar, Istanbul, Turkey.

Corresponding author:

Hasan SONTAS, DVM, PhD,
Resident in Department of Veterinary Clinical Sciences,
Faculty of Veterinary Medicine,
University of Padova, Legnaro, Padova, Italy.
Email: bhsontas@gmail.co

HISTORY

A 13 year-old, 7 kg, sexually intact, poodle bitch was admitted to the veterinary teaching hospital with a >12 months history of multiple mammary gland masses. Accompanying complaints were a non-productive and chronic cough, lethargy and anorexia. On physical examination the animal was depressed with normal appearance and conformation. The rectal temperature,

pulse and respiratory rates were within reference ranges. On palpation irregular shaped, firm masses less than 5 cm in diameter were identified in all 8 mammary glands. No ulceration or hemorrhage was noticed in any of the glands. Hematological findings were within normal ranges while levels of urea, alkaline phosphatase, calcium, glucose, total protein were elevated. Radiographs of the thorax and abdomen were obtained (Figure 1A-B).

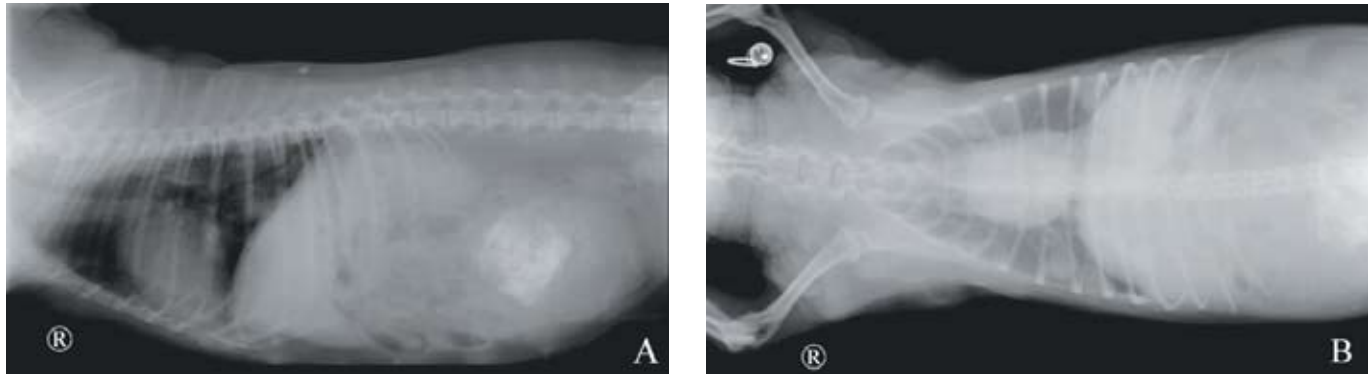


Fig. 1.

Right lateral (A) and ventrodorsal (B) radiographic views of the thorax and abdomen of a 13-year-old, sexually intact Poodle bitch presented with multiple mammary gland masses.

Determine whether additional imaging studies are required or make your diagnosis from Figure 1-then turn the page

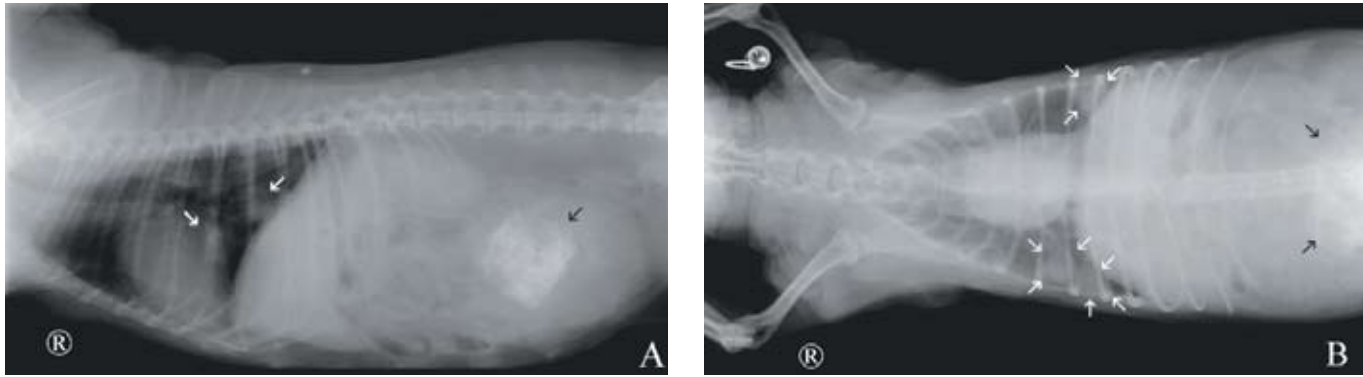


Fig. 2. Same radiographic views as in Figure 1. A-On lateral radiography, notice the two solitary pulmonary masses approximately 3 cm in diameter; one mass is overlying the caudal aspect of the heart and the other mass is in the right caudal pulmonary lobe (white arrows). Note, a large, round mass with mineralization in the caudo-abdominal region (black arrow). B-On the ventrodorsal radiographic view, note the similar sized two pulmonary masses in the right caudal lobe and another pulmonary mass in the left caudal lobe (white arrows). The calcified mass in the caudo-abdominal region can also be seen (black arrow).

RADIOGRAPHIC FINDINGS AND INTERPRETATION

Three solitary thoracic masses approximately 3 cm in diameter are visible in the left and right caudal pulmonary lobes (Figure 2). Differential diagnoses included abscesses, fungal granulomas, lymphomatoid granulomatosis, hematoma, pneumonia, infarcts, cysts and primary or secondary neoplasms. A large, irregular shaped mass with mineralization in the caudal abdominal region possible involving the uterus, colon/rectum or urinary bladder is evident. Differential diagnoses for a sexually intact bitch presented with a calcified caudo-abdominal mass include pregnancy, mummified fetus, gastrointestinal foreign body, enterolithiasis, urolithiasis, dystrophic calcification of necrotic lesions and tumors arising from ureter, uterus and bladder.

After the detection of the large calcified mass in the x-ray, the abdomen was palpated and a firm, irregular shaped, moveable mass (approximately 10 cm in diameter) was detected in the lower portion of the abdomen. No pain or discomfort were elicited on abdominal palpation. Abdominal ultrasonography of this dog revealed a homogenous and hypoechoic mass with hyperechoic margins at the caudal abdomen. No evidence of fetal structures was determined. On the basis of the radiographic, ultrasonographic and general examination findings, a tentative diagnosis of mammary gland tumor with pulmonary metastasis and uterine tumor was made.

Bilateral radical mastectomy and ovariohysterectomy were performed at the same time. During laparotomy an irregular shaped, firm mass, 6x7x12 cm in size, was identified in the uterine body. Histopathological examination of the excised tissues revealed a malignant mix tumor of the mammary glands, chondroblastic osteosarcoma of the uterus and papillary ovarian adenocarcinoma. Following surgery, the dog was treated with 30 mg/m² BSA doxorubicin IV every three weeks. After the second treatment, thoracic radiographs demonstrated disappearance of one of the

nodules and reduction in the nodular density. However, the owner elected to euthanize the dog about four months after the initial treatment for a reason unrelated to the disease.

DISCUSSION

The lungs are the second most common site for tumor metastasis in canine mammary tumors accounting for 53% of the metastasis (1). Therefore, radiographic evaluation of the lungs is essential even though no clinical signs are observed. Generally, well defined nodules, ill-defined nodules and diffuse pulmonary interstitial opacities not less than 5 mm in size are indicative of pulmonary metastasis in radiographic views (2). The sensitivity, specificity and accuracy of thoracic radiography for the detection of metastasis have been reported to be 65%, 97% and 87%, respectively (2). Three thoracic radiographs with right lateral recumbent, left lateral recumbent and ventro-dorsal projections should be evaluated although right lateral recumbent view was found to be the most sensitive of the three (3). The accuracy of radiography for detection of pulmonary metastasis depends on several factors including intrinsic factors, radiographic technique and interpretation (3). To the authors' knowledge, neither the use nor the accuracy of computed tomography in the diagnosis of pulmonary metastasis has been investigated in dogs.

Even though chemotherapy is routinely used in women with metastatic breast cancer with a negative hormone receptor status, very few reports are available in dogs (4, 5). A long-term partial remission of 12 and 15 months' duration was observed in two dogs treated with 30 mg/m² doxorubicin IV every three weeks (4). Pruritus, anorexia, diarrhea, vomiting and colitis were the reported -effects (4). In another report (5), a combination treatment with methotrexate (0.3 mg/kg, IV), cyclophosphamide (1mg/kg/day, PO) and vincristine (0.0125 mg/kg, IV) provided survival for more than three years after surgery in an Irish setter bitch. Vomiting, mild posterior paresis and knuckling of the hind paw were

observed during the treatment period. Uterine neoplasms are less frequently reported in the bitch and the clinical signs are variable which depend on size and location of the tumor, presence of metastatic disease and any accompanying disease such as pyometra (6). Radiographic findings are non-specific and may only demonstrate a focal, soft tissue mass positioned between the distal colon and bladder, but the localization of the uterus may be difficult. In this dog, the uterine tumor was radiographically detected as a calcified mass because of the histopathological type of the tumor consisted of chondroblasts and osteoclasts.

As in this case, ovarian tumors are generally detected incidentally during ovariectomy/ ovariohysterectomy or on postmortem examination in dogs that do not have clinical signs referable to the tumor such as a space-occupying mass, ascites due to tumor dissemination, or persistent proestrus/estrus of more than 30 days' duration (6). Ovarian adenocarcinoma of the dog presented here could not be detected radiographically because of its tissue content. Among ovarian tumors, solely teratomas/teratocarcinomas (malignant form) have a typical radiographic finding of a calcified abdominal mass with mineralization due to the presence of highly mineralized well differentiated tissues, including teeth and bones (6). Ovarian ultrasonography could have been performed in this dog for the detection of the tumor, however, it was not considered because of the absence of clinical signs related to an ovarian tumor.

An interesting aspect of this case was the presence of three tumors in one dog. The etiologies of canine genital (with the exception of the transmissible venereal tumor) or mammary tumors are unknown (6, 8-10). However, it has been suggested that both conditions are hormone-dependent, and especially steroid hormones are thought to play a role in the pathogenesis of tumor development. The facts that supported this claim include a) the risk of genital and mammary tumor development is higher in intact bitches than in spayed bitches; b) occurrence of mammary neoplasia may be prevented in bitches spayed before puberty; c) dogs with genital tumors also had follicular cysts, estrogen-producing tumors and endometrial hyperplasia; and d) combined or long-term treatment with estrogenic compounds or progestagens may

result in development of genital tumors in the bitch (8-10). In conclusion, ovariectomy or ovariohysterectomy should be considered for animals not intended for breeding because of the potential health benefits of the surgery such as decreased risk of mammary and ovarian neoplasia, or a decreased risk of pyometra, although an increase in the incidence of urinary incontinence or obesity may be observed in bitches after spaying.

REFERENCES

1. Moulton, J. E.: Tumors of the mammary gland. In: Moulton, J.E. (ed.) Tumors in Domestic Animals. 3rd ed. University of California Press, London, UK. 518-552, 1990.
2. Tiemessen, I.: Thoracic metastases of canine mammary gland tumors. *Vet. Rad.* 30:249-252, 1989.
3. Lang, J., Wortman, J. A., Glickman, L. T., Biery, D. N., Rhodes, W. H.: Sensitivity of radiographic detection of lung metastases in the dog. *Vet. Rad.* 27:74-78, 1986.
4. Hahn, K. A., Richardson, R. C., Knapp, D. W.: Canine malignant mammary neoplasia: biological behavior, diagnosis and treatment alternatives. *J. Am. Anim. Hosp. Assoc.* 28:251-256, 1992.
5. Riley, J. H. and Riley, M. G. I.: Metastatic mammary carcinoma treated with cytotoxic drugs. *Vet. Rec.* 111:8-11, 1982.
6. McEntee, M. C.: Reproductive oncology. *Clinic. Tech. Small Anim. Pract.* 17:133-149, 2002.
7. Diez-Bru, N., Garcia-Real, I., Martinez, E. M., Rollan, E., Mayenco, A., Llorens, P.: Ultrasonographic appearance of ovarian tumors in 10 dogs. *Vet. Rad. Ultrasound* 39:226-233, 1998.
8. Kydd, D. M. and Burnie, A. G.: Vaginal neoplasia in the bitch: a review of forty clinical cases. *J. Small Anim. Pract.* 27:255-263, 1986.
9. Jubb, K. V. F., Kennedy, P. C., Palmer, N.: Neoplastic diseases of the tubular genitalia. In: Jubb, K. V. F., Kennedy, P. C., Palmer, N. (eds), *Pathology of Domestic Animals*, 4th edn. Academic Press Inc., Florida, pp. 450-454, 1993.
10. Fiorito, D. A.: Hyperestrogenism in bitches. *Compend. Contin. Educ. Pract. Vet.* 14:727-729, 1992.