

Dermal Angiokeratoma in a Pet Ferret (*Mustela Putorius furo*)

Wolfe, H. A.,^{1,2} Eshar, D.,^{1*} Higbie, C.T.^{1,3} and Andrews, G.A.¹

¹ College of Veterinary Medicine, Kansas State University, 101 Trotter Hall, Manhattan, KS, USA 66505.

² Lake Mary Veterinary Clinic, 2889 West Lake Mary Blvd, Lake Mary, FL, USA 32746 (Present address).

³ School of Veterinary Medicine, Louisiana State University, Skip Bertman Drive, Baton Rouge, LA 70803 (Present address).

* **Corresponding author:** Dr. David Eshar, College of Veterinary Medicine, Kansas State University, 101 Trotter Hall, Manhattan, KS, USA 66505.
Tel: 785-532-5660. Email: deshar@vet.k-state.edu.

ABSTRACT

A 7-year-old female spayed pet ferret (*Mustela putoriusfuro*) was evaluated for extensive alopecia and pruritus of a few months' duration. Physical examination had also revealed a dermal mass on the dorsum of the head. The cranial lesion was surgically removed and the histopathology was consistent with a diagnosis of angiokeratoma. To the author's knowledge, this is the first report to describe the clinical presentation, diagnosis and treatment for dermal angiokeratoma in a ferret.

Keywords: Ferret; Angiokeratoma; Neoplasia; Skin; *Mustela putoriusfuro*.

INTRODUCTION

Angiokeratoma is a benign vascular neoplasm that has not previously been reported in domestic ferrets. It has been rarely reported in dogs where it is most often seen on the third eyelid and conjunctiva, but it may also manifest on the superficial dermis of any other site (1). In humans, these masses tend to appear as small, bluish to black rough warty growths, and are mostly located on the lower extremities (2).

CASE REPORT

A 7-year-old, 984-g female spayed pet ferret (*Mustela putoriusfuro*) was evaluated by the Exotics and Zoological Medicine Service at Kansas State University Veterinary Health Center for chronic skin lesions. The ferret had extensive alopecia that was first noticed by the owner a few months prior to the visit, along with what was believed to be an excoriation on the dorsum of her head. The ferret was housed indoors and was allowed free roam of the house for a few hours each day. Her diet consisted of a commercial high protein ferret kibble. The owner did not report any changes in appetite, urination or defecation.

On physical exam the alopecia extended from the top of the ferret's head and down the spine to the mid-abdomen. The alopecia was also present dorsally over the feet. The skin was scaly, dry, thin and reddened. A raised erythematous dermal mass was present on the head (or top of the head) (Figure 1). The spleen palpated enlarged with a possible mass cranial to the right kidney. No other abnormalities were noted following a complete physical exam. Complete surgical excision and histopathological examination were recommended in order to diagnose the dermal mass on the head. In addition, ferret adrenocortical disease was considered based on the pattern of alopecia, pruritus, excoriation, and the presence of a mass cranial to the right kidney. A ferret adrenal hormone panel and abdominal ultrasonography were recommended for further testing, but the owner only allowed the surgical removal and histopathology of the cranial dermal lesion.

The ferret was premedicated using a mixture of midazolam (0.25 mg/kg intramuscularly; Akorn Inc., Lake Forest, IL USA) and butorphanol (0.25 mg/kg intramuscularly; Torbugesic, Fort Dodge Animal Health, Fort Dodge, IA USA). General anesthesia was induced using a small face

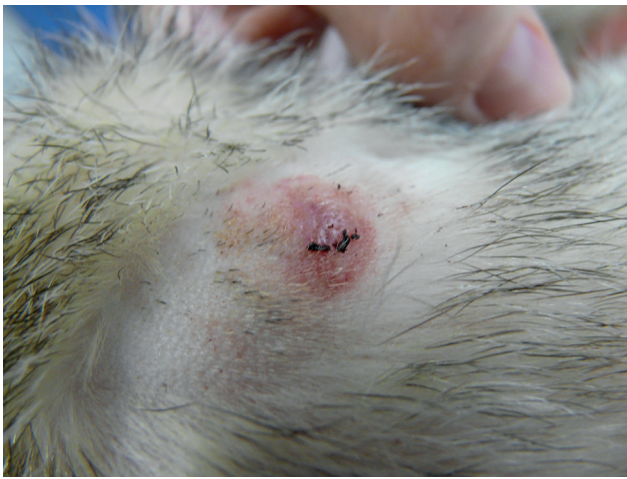

Figure 1: Image of this ferret at presentation showing the raised dermal mass on the head.

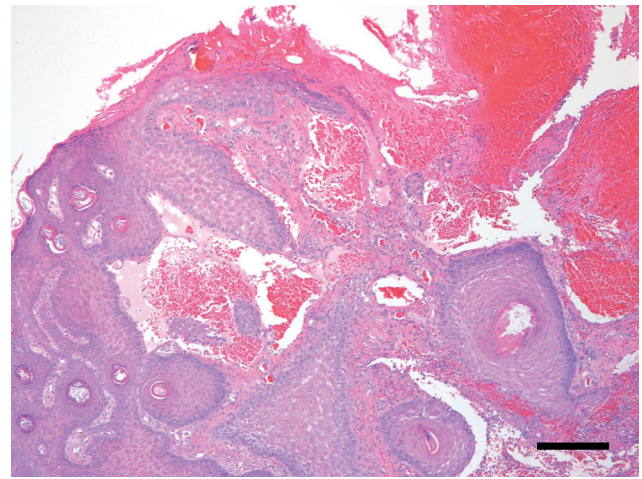


Figure 2: Photomicrograph of ferret cutaneous angiokeratoma characterized by superficial dermal cavernous vascular spaces filled with blood and lined by a single layer of well differentiated endothelial cells. The epidermis is hyperplastic with trabeculae of epithelium that extend between and partially surround the vascular spaces. H&E stain.
Bar = 200 μ m

mask with 5% isoflurane gas (IsoFlo; Abbott Laboratories, North Chicago, IL USA) in 2L/min oxygen. Following induction, the ferret was maintained under general anesthesia using a fitted face mask and non-rebreathing circuit using 2.5% isoflurane delivered via 1.5 L/min of oxygen. Body temperature was monitored rectally using a handheld digital thermometer and maintained using a warm water blanket and heating packs. Vital signs were monitored using a stethoscope, a Doppler (Parks Doppler System Model 811-B; Parks Medical Electronics, Inc., Aloha, OR USA) and a pulse oximeter (Nellcor Handheld Pulse Oximeter N20PA, Covidien, Dublin, Ireland). The area around the mass was aseptically prepared using a standard technique. A full thickness biopsy of the mass on the head was obtained using a disposable Baker's biopsy punch (SklarTru-Punch disposable biopsy punch, 5 mm; Sklar, West Chester, PA USA). This also resulted in complete excision of the mass. The surgical site was closed using 4-0 polydioxane monofilament absorbable suture (PDS II™; Ethicon, Somerville, NJ USA) in a simple cruciate pattern. Flumazenil (0.05 mg/kg intramuscularly; Ben Venue Labs, Bedford, OH USA) was given to assist an uneventful anesthetic recovery. The tissue was placed in 10% buffered formalin and submitted for histopathologic examination.

The histopathologic diagnosis of this mass was of an angiokeratoma (Figure 2). The dermis contained a neoplasm composed of cavernous vascular spaces filled with blood and lined by a single layer of well differentiated endothelial cells. The overlying epidermis was hyperplastic with trabeculae

of epithelial cells that extended between the vascular spaces and partially surrounded them. The epidermis was focally ulcerated and covered with clotted blood. Excision of the mass appeared complete.

DISCUSSION

Angiokeratoma is a histologically benign tumor that has been described as an uncommon variant of a dermal hemangioma (3). While this form of neoplasia has not been reported in ferrets, it has been seen in domestic dogs. In a total of 8 angiokeratoma cases reported in dogs, each tumor presented as a single small, red, raised mass (4). Recurrence was only seen in one of the aforementioned cases, but there was no evidence of invasiveness or metastasis in that patient (4).

Other vascular tumors such as hemangioma and hemangiosarcoma are occasionally reported in ferrets (5). Similar to the lesion in this case, they typically have the appearance of a small, raised, black mass, and are histologically characterized as well circumscribed, blood filled masses lined by endothelial cells (5, 6, 7). While dermal hemangiomas are rarely seen in ferrets, they are usually located on the head, face or feet, although they can occur anywhere on the body (6). Angiokeratoma grossly appears very similar to dermal hemangiomas. Although angiokeratoma and hemangioma share many histologic characteristics, the only way to differ-

entiate these tumors is by histopathology as angiokeratomas show marked hyperplasia of the overlying epidermis, which appeared to invade between the vascular spaces of the superficial dermis (3).

Various other skin tumors have more commonly been reported in ferrets and were considered as differential diagnoses in this case. Two of the most commonly reported tumors are of basal cell and mast cell origin (6, 8). One retrospective study of fifty-seven cutaneous neoplasms in ferrets reported 58% basal cell tumors, 16% mast cell tumors, 11% fibromas, and 4% hemangiomas (7). Another study showed that among 763 reported cases of ferrets with cutaneous neoplasia, the vast majority were mast cell tumors at 33%, nearly equal with basal cell tumors at 30% (6). Hemangiomas accounted for 8.5% of reported neoplasms. The remaining masses included preputial gland tumors at 4%, lymphoma at 2.5%, and leiomyosarcoma, squamous cell carcinoma, spindle cell sarcoma, apocrine gland cystadenoma, mammary gland adenoma, fibroma, fibrosarcoma, leiomyoma, and epitheliotrophic lymphoma each at roughly 1% occurrence (6). Lastly, a retrospective study of 574 ferrets reported 83 integumentary tumors. Of these, 26 were unspecified tumors (9). The majority of the remaining neoplasms included mast cell tumor (n=17), basal cell tumor (n=6), and squamous cell carcinoma (n=6), with only one hemangioma reported in that study.

Due to the benign nature of angiokeratomas in dogs, complete excision of the mass will generally be curative (1, 4). This can be accomplished either by surgical excision or by using a punch biopsy tool as was performed in this case (6, 10). Histological examination of the excised mass is imperative to obtain a definitive diagnosis and to ensure that the margins are free of neoplastic cells in cases of a malignant dermal neoplasia.

This report describes a clinical case of a rare cutaneous

neoplasm in a pet ferret. This neoplasm should be added to the list of grossly similar dermal masses often observed in ferrets.

EULOGY – DR. GORDON ALLAN ANDREWS,
DVM, PHD, DIPLOMATE ACVP

Dr. Andrews served for many years as a diagnostic pathologist at the College of Veterinary Medicine, Kansas State University. Exotic animal medicine is extremely challenging given the relative limited scope of knowledge of their diseases. The authors of this manuscript feel fortunate to have had the opportunity to learn from Dr. Andrews and work together with him to promote the knowledge of non-common species.

REFERENCES

1. Vala, H., and Esteves, F.: A Case of Angiokeratoma. *Vet. Pathol.* 38:324-325, 2001.
2. Imperial, R., and Helwig, E.: Angiokeratoma: A Clinicopathologic Study. *Arch. Dermatol.* 95:166-175, 1967.
3. Gross, T.L., Ihrke, P.J., Walder, E.J., and Affolter, V.K.: *Skin Diseases of the Dog and Cat: Clinical and Histopathologic Diagnosis*, Blackwell Science, Iowa, 2005.
4. George, C., and Summers, B.A.: Angiokeratoma: A benign vascular tumour of the dog. *J Small Anim. Pract.* 31:390-392, 1990.
5. Fox, J.G., Muthupalani, S, Kiupel, M, and Williams B.: Neoplastic Diseases. In: Fox, J.G. and Marini, R.P. (Eds.): *Biology and Diseases of the Ferret*. Wiley, Iowa, p. 601, 2014.
6. Kanfer, S., and Reavill, D.R.: Cutaneous Neoplasia in Ferrets, Rabbits, and Guinea Pigs. *Vet. Clin. N. Am-Exotic.* 16:579-598, 2013.
7. Parker, G.A., and Picut, C.A.: Histopathologic Features and Post-surgical Sequelae of 57 Cutaneous Neoplasms in Ferrets (*Mustela putoriusfuro*). *Vet. Pathol.* 30:499-504, 1993.
8. Kelleher, S.A.: Skin Diseases of Ferrets. *Semin Avian Exot Pet.* 11:136-140, 2002.
9. Li, X., Fox, J.G., and Padrid, P.A.: Neoplastic Diseases in Ferrets: 574 cases. *J. Am. Vet. Med. Assoc.* 212:1402-1406, 1998.
10. Quesenberry, K.E., and Carpenter, J.W.: *Ferrets, Rabbits, and Rodents: Clinical Medicine and Surgery*, Elsevier/Saunders, Missouri, 2012.