

Diaphragmatic Hernia in a Kid – First Case Reported

Narayanan, M. K.,¹ Sarangom, S. B.,^{1*} Devanand, C. B.,¹ Antonia, N. A.,¹ Jinu, J.,¹ Gadhafi, K. P.,¹ Syam, K. V.² and Anoop, S.¹

¹ Department of Veterinary Surgery and Radiology, College of Veterinary and Animal Sciences, Kerala Veterinary and Animal Sciences University, Mannuthy, Thrissur, Kerala, India – 680 651.

² Teaching Veterinary Clinical Complex, College of Veterinary and Animal Sciences, Kerala Veterinary and Animal Sciences University, Mannuthy, Thrissur, Kerala, India – 680 651.

* **Corresponding Author:** Sherin B. Sarangom, MVSc., Teaching Assistant, Department of Veterinary Surgery and Radiology, College of Veterinary and Animal Sciences, Kerala Veterinary and Animal Sciences University, Mannuthy, Thrissur, Kerala, India – 680651. Tel: +91 9447310472 Email: sbs04vet@gmail.com

ABSTRACT

A three month old male kid (*Capra hircus*) was presented to the clinic with an extensive soft diffuse swelling on the right ventro-lateral thorax due to an automobile accident. By clinical, radiographic and ultrasonographic examination, diaphragmatic herniation of abdominal organs into the thoracic cavity was diagnosed. Herniorrhaphy was performed and intra-operatively, ribs 9-11 were found fractured below the costochondral junction. Postoperative medication and monitoring led to an uneventful recovery. To the best knowledge of the authors this is the first report of a successful diaphragmatic herniorrhaphy in a goat kid or any small ruminant.

Keywords: Diaphragmatic hernia, Kid Goat, Radiography, Diaphragmatic silhouette.

INTRODUCTION

Diaphragmatic hernia (DH) is the passage of abdominal viscera into the thoracic cavity through a congenital or acquired opening in the diaphragm. DH may be congenital or acquired. Congenital diaphragmatic hernias are seldom diagnosed or recognized compared to traumatic hernias. Despite of etiology, DH is a surgical emergency and the condition has been reported in dogs, cats, horses, pigs, calves, cattle and buffaloes (1, 2, 3, 4, 5, 6, 7). However the condition was not yet reported in small ruminants like sheep and goat. DH was previously reported in a goat as an incidental postmortem finding (8). The animals presented with DH may gradually become lethargic and indisposed and often the owners may not agree to pursue treatment and rather opt for euthanasia. At times, treatment may be chosen considering the genetic value of the animal. The post-operative survival rates after repair of DH was found to be good in large animals as well as small animals (9, 10, 11). However mortality is not infrequent particularly in animals presented with adverse respiratory

complications and concurrent injuries (2, 3, 12). The present case of DH with fractured rib was managed successfully and is believed to be the first description in a goat kid or any small ruminant.

CASE HISTORY

A three month old male kid (*Capra hircus*) weighing 6 kilograms was presented to the Teaching Veterinary Clinical Complex (College of Veterinary and Animal Sciences, Kerala Veterinary and Animal Sciences University) immediately after an automobile accident. The animal was dull and depressed and an extensive soft diffuse swelling was noticed along the right ventro-lateral thorax. The abdomen was found to be deflated.

The kid showed tachypnea (30 breaths/min) and mild dyspnea when excited. The rectal temperature (39.6°C) and heart rate (78 beats/min.) were within normal range. The pulse was strong and regular. The conjunctival mucous membranes were pale pink and the capillary refill time was <2

seconds. The respiratory movements of the right chest were found to be decreased compared to the left side. On auscultation of the left side of chest, normal heart sounds and increased lung sounds were heard but on the right side of chest, the sounds were muffled along with intestinal sounds. No signs of pain or discomfort were noticed anywhere on the body except at the area of swelling. The margin of the ribs could not be positively felt along the region of swelling. Signs of any sprain, fracture or dislocation could not be detected on orthopedic examination.

The lateral radiograph of the thorax revealed an incomplete diaphragmatic silhouette with gas filled gastro-intestinal organs in the thoracic cavity. Dorsoventral radiograph confirmed herniation through the right side of the diaphragm. Only the caudal portion of the left lung was properly filled with air. Ultrasonographic evaluation identified forestomachs, spleen, small intestine, liver and gall bladder in the thoracic cavity that has herniated through the rent on the right ventrolateral diaphragm at the musculotendinous junction. The complete hematology and serum biochemistry revealed no abnormalities. Hemogram revealed negative status for blood protozoa and/or rickettsial infections, and hematological values were within normal range.

TREATMENT

The herniorrhaphy was attempted on the same day under general anesthesia along with local infiltration analgesia as the cardiopulmonary function of the animal was generally stable. The kid was premedicated with diazepam (Calmpose,

Ranbaxy laboratories Limited, Baddi, Himachal Pradesh, India) at the rate of 0.2 mg/kg body weight intravenously. Preoperatively, ceftriaxone (Intas Pharmaceuticals Ltd., Ahmedabad, Gujarat, India) 100 mg and ketoprofen (Neoprofen, Pfizer Animal Health India Limited, Haridwar, Uttarakhand, India) at the rate of 3.3 mg/kg body weight were administered intravenously. Anesthesia was induced with intravenous ketamine (Aneket, Neon Laboratories Limited, Thane, Maharashtra, India), administered at the rate of 5 mg/kg body weight and was maintained with isoflurane (Forane, Abbott Laboratories Ltd., Queen Borough, Kent, United Kingdom) and oxygen. The jugular vein was catheterized for perioperative administration of intravenous Ringer's Lactate (RL, Parenteral drugs (India) Limited, Indore, Madhya Pradesh, India) at the rate of 10 mL/kg/hr. Four mL of 2% lignocaine hydrochloride (Lignocaine Hydrochloride Injection 2%, A.P.J. Laboratories Ltd., Sirmour, Himachal Pradesh, India) was linearly infiltrated along the proposed site of incision. An additional 5 mg ketamine was given intravenously.

The kid was positioned in supine position and a transabdominal approach was resorted to with a concentric incision of 7.5 cm in length caudal to xiphoid and parallel to costal arch on right cranial quadrant of ventral abdomen. Once the abdominal cavity was opened, the hernia was confirmed and the herniated contents included the forestomachs, omentum, spleen, small intestine, liver and gall bladder. An 8 cm long tear was noticed along the right side of diaphragm at the musculotendinous junction. Intra-operatively, ribs 9-11 were found fractured below the costo-chondral junction.



Figure 1: Kid presented after accident with a swelling on the lateral thorax.

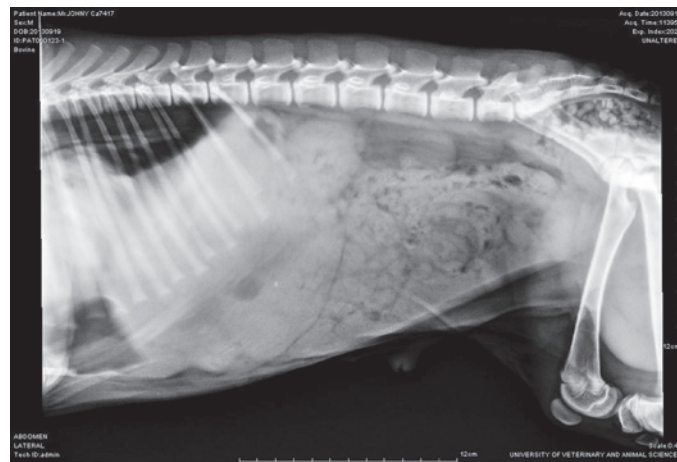


Figure 2: Lateral radiograph showing incomplete diaphragmatic silhouette.

Adhesions, fibrin deposition and congestion were not observed on the herniated viscera.

The abdominal organs were gently repositioned and the diaphragm was sutured in simple continuous sutures pattern using 2-0 USP polyglactin 910 (Relyon Glactin, MCo Hospital Aids Pvt. Ltd., Hubli, Karnataka, India). An additional layer of sutures were applied in a simple interrupted manner using 2-0 USP polypropylene (Prolene, Johnson and Johnson Limited, Aurangabad, Uttar Pradesh, India). Towards the ventral side, the diaphragm was fixed onto the *manubrium sterni* and the thoracic wall using 2-0 USP polyglactin 910. The lungs were hyperinflated before the application of the final suture on the diaphragm. A butterfly needle connected to a syringe was used to reestablish the negative pressure inside the right thorax. The rib fracture was not treated and was left as such. The muscles and subcutaneous tissues were opposed using 2-0 USP polyglactin 910 in simple continuous suture pattern followed by skin using polyamide (Ethilon, Johnson and Johnson Limited, Aurangabad, Uttar Pradesh, India). A cotton gauze stent was also fixed over the suture line. Postoperatively, ceftriaxone and ketoprofen were administered intravenously. Lateral thoracic and abdominal radiograph showed re-established diaphragmatic silhouette along with repositioned abdominal organs. Confinement and rest was advised to enable healing of fractured ribs.

Upon observation on second post-operative day, the kid was bright and alert. The animal started sucking dam's milk. Thoracic auscultation showed normal lung sounds on both sides of the chest. Mild subcutaneous emphysema was no-

ticed anterior to the suture line dorsally that resolved by the third post-operative day. Based on the perioperative surgical evaluation and the postoperative clinical response, the prognosis was assessed to be good. Post-operative antibiotics and analgesics were administered for 7 additional days. The skin sutures were removed on the 10th post-operative day. Post-operative complications were not noticed since then and the animal had an uneventful recovery.

DISCUSSION

Traumatic diaphragmatic hernias are infrequent in animals. It may be caused by mechanical factors like trauma due to automobile accidents as in the present case, penetrating injuries, pregnancy, act of parturition and falls (13, 14, 15). Immediate recognition and diagnosis of the condition is necessary in order to plan the treatment strategies.

The usual presentation of DH includes a wide range of clinical signs depending on the size and the location of the hernia and the amount and the type of viscera involved (14, 15). DH should be suspected if any animal is presented with dyspnea, bilateral asymmetric lung sounds and intestinal sounds on thoracic auscultation especially immediately after a traumatic incident (4, 14, 15, 16). In the present case, the clinical signs were nonspecific and hence the condition had to be differentially diagnosed from edema and inflammatory swelling due to trauma, subcutaneous emphysema, ventral abdominal hernia, pneumocele, unilateral pneumothorax, pneumonia and pleural effusion. Thoracic radiographs are helpful in diagnosing the condition and the ultrasono-

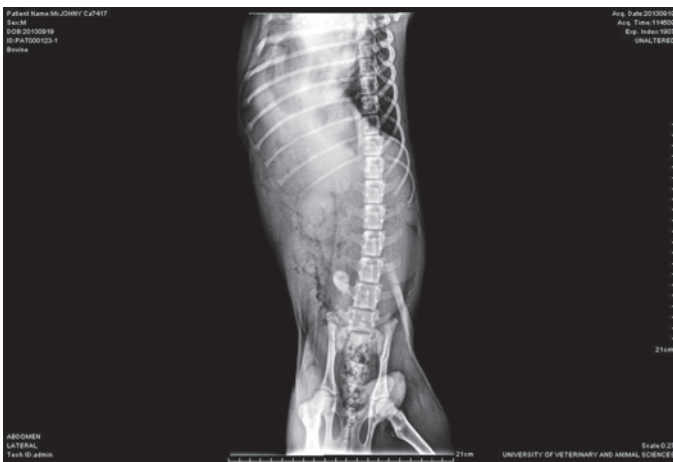

Figure 3: Dorso-ventral radiograph showing herniation through the right hemi-diaphragm

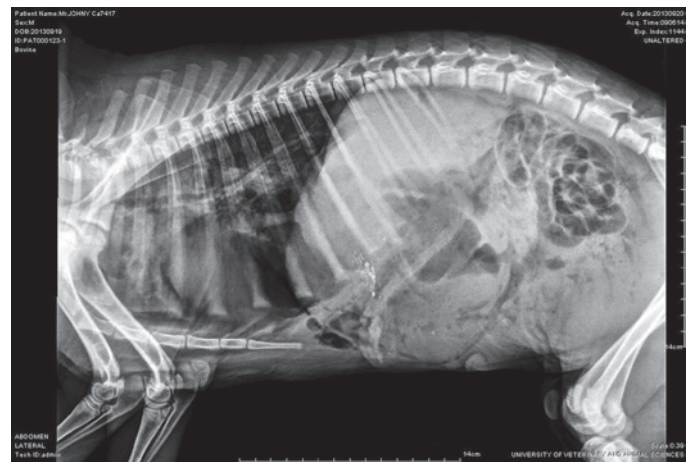


Figure 4: Post-operative lateral radiograph showing re-established diaphragmatic silhouette

graphic evaluation enable to confirm the diagnosis (4, 6, 15, 17). Diagnostic tools like contrast radiography may provide an additional picture regarding the extent of hollow organs involved in the herniation (6, 9, 12, 15). Invariably, reticulum, omentum, omasum, abomasum, liver, gall bladder, spleen and intestinal loops have been reported to have herniated in cattle and buffaloes (4, 9, 12, 14). Exploratory laparotomy and thoracic laparoscopy could also be considered for the diagnosis of DH (3, 11, 14).

The repair of DH required preoperative, perioperative and postoperative considerations. The preoperative stabilization of the animal, the antibiotic and analgesic therapy, the possible anesthetic complications like hypoventilation and hypoxia due to atelectatic lung and the stabilization of cardio-pulmonary function prior to surgery have to be invigilated (4, 11, 17). The general anesthetic and local analgesic drug combination was comparatively safe and provided effective anesthesia and analgesia for performing herniorrhaphy. As the animal was presented shortly after trauma and immediate surgical intervention was attempted, adhesions and fibrin deposition were not set in. Also, the absence of any strangulated viscera provided a favorable prognosis. The duration of illness, size and location of the diaphragmatic tear and the amount of compromised viscera play a significant role in the prognosis of DH (11, 12, 18, 19). There was no evidence of shock and hence tachypnea can be attributed to be the result of a reduced lung capacity due to pulmonary compression or conscious pain perception at the injured site of diaphragm (19). The anticipated complication was associated with rib fracture and the possible flail chest (2, 20). Moreover, the repair of fractured rib below the level of costochondral junction was not attempted. The fixation of the repaired diaphragm on to the *manubrium sterni* and ventro-lateral thoracic wall considerably reduced the tension on the fractured rib. The extent of the tear on the diaphragm was in the range of an opposable length. The transabdominal approach made the repair convenient and easy. An additional prosthetic mesh with a bio-absorbable layer has to be considered for the closure of large or less pliable congenital and traumatic rents and to reduce the tension on the repaired diaphragm (11). The negative pressure was successfully reestablished and hence thoracic drain was not placed.

The early presentation, rapid diagnosis, immediate surgical intervention, favorable response to anesthetic and analgesic drug combination, intra-operative monitoring, minimal

intra-operative complication, skill of the surgeon and assistants, postoperative medication and monitoring in addition to the appreciable mind-set of the owner led to an uneventful recovery of the animal. Also it was the fractured ribs got stabilized by rest and confinement. According to the best of the authors' knowledge, this is the first report of successful diaphragmatic herniorrhaphy in a kid.

ACKNOWLEDGEMENT

The authors thank the Dean, College of Veterinary and Animal Sciences, Mannuthy, Thrissur, Kerala, India for providing necessary facilities for the study. The help and support rendered by the Senior Veterinary Surgeon and Veterinary Surgeon of the District Veterinary Centre, Thrissur, Kerala, India is also deeply acknowledged.

REFERENCES

1. Minihan, A. C., Berg, J. and Evans, K. L.: Chronic diaphragmatic hernia in 34 dogs and 16 cats. *J. Am. Anim. Hosp. Assoc.* 40:51-63, 2004.
2. Schmiedt, C. W., Tobias, K. M. and Stevenson, M.: Traumatic diaphragmatic hernia in cats: 34 cases (1991-2001). *J. Am. Vet. Med. Assoc.* 222:1237-1240, 2003.
3. Romero, A. E. and Rodgerson, D. H.: Diaphragmatic herniation in the horse: 31 cases from 2001-2006. *Can. Vet. J.* 51:1247-1250, 2010.
4. Bellavance, A., Bonneville-Hebert, A., Desrochers, A. and Fecteau, G.: Surgical correction of a diaphragmatic hernia in a newborn calf. *Can. Vet. J.* 51:767-769, 2010.
5. Schwartz, K. J.: Epizootics of diaphragmatic hernias in swine. *J. Vet. Diagn. Invest.* 3:362-364, 1991.
6. Saini, N. S., Kumar, A., Mahajan, S. K. and Sood, A. C.: The use of ultrasonography, radiography and surgery in successful recovery from diaphragmatic hernia in a cow. *Can. Vet. J.* 48:757- 759, 2007.
7. Patel, J. B., Mistry, J. N., Patel, P. B., Suthar, B. N. and Suthar, D. N.: Diaphragmatic herniorrhaphy without positive pressure ventilation in buffaloes. *Indian J. Vet. Surg.* 33:55-56, 2012.
8. Tafti, A. K.: Diaphragmatic hernia in a goat. *Aust. Vet. J.* 76:166, 1998.
9. Kumar, A., Saini, N. S., Mohindroo, J., Sangwan, V., Mahajan, S. K., Raghunath, M. and Singh, N.: Long term outcomes of survivors of diaphragmatic herniorrhaphy in crossbred cows and buffaloes. *Indian J. Anim. Sci.* 82:971-975, 2012.
10. Gibson, T. W. G., Brisson, B. A. and Sears, W.: Perioperative survival rates after surgery for diaphragmatic hernia in dogs and cats: 92 cases (1990-2002). *J. Am. Vet. Med. Assoc.* 227:105-109, 2005.
11. Kelmer, G., Kramer, J. and Wilson, D. A.: Diaphragmatic hernia: Treatment, complication, and prognosis. *Comp. Cont. Ed. Equine Edition.* 3:37-45, 2008.

12. Saini, N. S., Sobti, V. K., Mirakhur, K. K., Singh, S. S., Singh, K. I., Bansal, P. S., Singh, P. and Bhatia, R.: Retrospective evaluation of 80 non-surviving buffaloes with diaphragmatic hernia. *Vet. Rec.* 147:275-276, 2000.
13. Boudrieau, R. J.: Pathophysiology of traumatic diaphragmatic hernia. In: Bojrab, M. J. (Ed.): *Disease mechanisms in small animal surgery*. Lea and Febiger, Philadelphia, pp. 103-108, 1993.
14. Singh, J., Fazili, M. R., Chawla, S. K., Tayal, R., Behl, S. M. and Singh, S.: Current status of diaphragmatic hernia in buffaloes with special reference to etiology and treatment: a review. *Indian J. Vet. Surg.* 27:73-79, 2006.
15. Kelmer, G., Kramer, J. and Wilson, D. A.: Diaphragmatic hernia: Etiology, clinical presentation, and diagnosis. *Comp. Cont. Ed. Equine Edition.* 3:28-35, 2008.
16. Ramprabhu, R., Dhanapalan, P. and Prathaban, S.: Comparative efficacy of diagnostic tests in the diagnosis of traumatic reticuloperitonitis and allied syndromes in cattle. *Israel J. Vet. Med.* 58:2-3, 2003.
17. Ricco, C. H. and Graham, L.: Undiagnosed diaphragmatic hernia- the importance of preanesthetic evaluation. *Can. Vet. J.* 48: 615-618, 2007.
18. Hart, S. K. and Brown, J. A.: Diaphragmatic hernia in horses: 44 cases (1986-2006). *J. Vet. Emerg. Crit. Care.* 19:357-362, 2009.
19. Sabev, S. P. and Kanakov, D. T.: Diaphragmatic hernia in a horse- a case report. *Vet. Arhiv.* 79:97-103, 2009.
20. Anderson, M. A., Payne, J. T., Mann, F. A. and Constantinescu, G. M. Flail chest: pathophysiology, treatment, and prognosis. *Comp. Cont. Ed. Pract. Vet.* 15:65-74, 1993.