

CLINICOPATHOLOGIC FINDINGS IN AN EXPERIMENTAL *SPIROCERCA LUPI* INFECTION IN DOGS

Aroch, I.,^{1*} Harrus, S.,¹ Amit T.,¹ Bark, H.,¹ Markovics, A.,¹ Hagag, A.,¹ Aizenberg, Z.,¹ and Lavy, E.¹

¹ Koret School of Veterinary Medicine
The Robert H. Smith Faculty of Agriculture, Food and Environment
The Hebrew University of Jerusalem, Israel.

² Department of Parasitology, Kimron Veterinary Institute, PO Box 12, Beit Dagan, Israel.

Short title: clinicopathologic findings in spirocercosis

*Corresponding author

Prof. Itamar Aroch

Koret School of Veterinary Medicine, The Hebrew University of Jerusalem,
PO Box 12, 76100 Rehovot, Israel

Tel: 972-3-9688556, Fax: 972-3-9604079, Email: aroch@agri.huji.ac.il

ABSTRACT

Spirocercas lupi is primarily a parasite of dogs, which typically causes esophageal nodules, aortic aneurysms and spondylitis. In this study, the hematology and serum biochemistry parameters in experimental canine spirocercosis were investigated. Ten beagle dogs were orally challenged with 40 infectious *S. lupi* larvae. One dog did not become infected. Two dogs died within 2 months post infection (PI) due to rupture of an aortic aneurism. Seven dogs became infected, presented with esophageal nodules and worm eggs in their feces. All were then treated with doramectin, survived and were followed for 21 months PI. Blood and fecal samples and esophagoscopy were performed periodically. Significant differences in the eosinophil counts were noticed in repeated measures between different time points during the study course. Eosinophil counts increased significantly ($P < 0.018$) two weeks PI and their relative and absolute counts were above the reference interval (RI) (18.8%; RI: 0-10%; $2.19 \times 10^9/L$; RI: $0.1-1.0 \times 10^9/L$, respectively). Both relative and absolute counts decreased significantly ($P < 0.018$) at 4 weeks PI (8.9% and $0.75 \times 10^9/L$, respectively) and remained within RI throughout the study course. Appearance of esophageal nodules, number of eggs shed in the feces and doramectin treatment had no association with eosinophil counts. There were no other significant differences in any hematologic and serum biochemistry analytes between different time points in repeated measures during the study course. In conclusion, with exception of a transient moderate eosinophilia, 14 days PI, hematologic and serum biochemistry abnormalities were absent in the early disease stages of experimental canine spirocercosis.

Key Words: Spirocercosis; Canine; Hematology; Eosinophil; Serum biochemistry; Nematode.

INTRODUCTION

The nematode *Spirocercas lupi* is mostly a parasite of dogs, although other animals, particularly carnivores might be affected (1, 2). It has a worldwide distribution, but is most prevalent in warm climates (1-4). It is transmitted to dogs through ingestion of coprophagous beetles or paratenic hosts, including birds, lizards and rodents (5). In Israel, it is most commonly transmitted through ingestion of the dung beetle *Ontophagus sellatus* (3), although in other countries, paratenic hosts seem to play a major role in disease transmission (5). A previous study indicated an emerging outbreak of spirocercosis in Israel. In spite of increased awareness, the disease prevalence and its geographic distribution have been increasing (3).

The pathogenesis of spirocercosis results from the migration and prolonged presence of infective larvae and adults in the host's tissues. Typical esophageal nodular masses, that might undergo neoplastic transformation, and aortic scars and aneurysms are the most frequent lesions, and are considered pathognomonic (5). Spondylitis and spondylosis of the caudal thoracic vertebrae (T6 -T12) are also typical lesions (3-8). Hypertrophic osteopathy is observed, mostly in the neoplastic form of the disease (9).

The clinical signs might related to the esophageal lesions that often interfere with swallowing and cause persistent regurgitation and/or vomiting (1, 5, 6, 10). Sudden death might be caused due to aortic aneurysm rupture resulting in

hemothorax (5, 11, 12). Abberant migration to different body organs has been reported in canine spirocercosis, causing a variety of clinical signs (5, 13, 14). Pyothorax and aortic thromboembolism have been reported in canine spirocercosis (5, 15, 16).

Spirocercosis can be suspected based on the clinical signs, and the diagnosis might be aided by radiography and computed tomography, demonstrating spondylosis and spondylitis of the thoracic vertebrae, aortic aneurisms and deformations and a caudal mediastinal thoracic mass (3-8). Radiography can lead to definite diagnosis of spirocercosis in those cases where esophageal nodule is present. However, it cannot definitely differentiate neoplastic from non-neoplastic cases or identify early spirocercosis cases, when thoracic involvement is absent (5). A definite diagnosis of spirocercosis is made by detecting the characteristic eggs in the feces of infected dogs through coproscopy or polymerase-chain reaction (PCR) using the mitochondrial cytochrome-C oxidase, subunit 1 (*cox1*) gene (17-19). The latter has been proven to be more sensitive compared to routine coproscopical methods (19), but it still relies on the presence of fertile female worms in the esophagus. Typical esophageal nodules might be demonstrated by esophagoscopy or post mortem (3, 5, 6, 20). Diagnostic methods that allow a definite diagnosis of spirocercosis are limited to the advanced stages of the disease, when adult worms are present in the esophagus (5). The ante mortem diagnosis of the disease in its early latent stages is almost impossible.

The aim of the present study was to evaluate and characterize the clinicopathologic changes that occurred during an experimental *S. lupi* infection in dogs, in order to assess their diagnostic usefulness in this disease, mostly in its early stages. The data for the study was collected during a study that assessed the prophylactic and therapeutic efficacy of doramectin in experimental canine spirocercosis. The results relating to the efficacy of doramectin have been published elsewhere (21, 22).

MATERIALS AND METHODS

Animals

Ten beagle dogs (6 males, 4 females), aged 6-10 years participated in this study. They were deemed healthy based on normal physical examinations, complete blood count (CBC), serum biochemistry and negative fecal flotations. These CBC and serum biochemistry results were used as base-line values for each dog in further analyses. Dogs were housed in separate cages in an enclosed kennel and fed a dry commercial canine diet. Feces were cleared and collected daily. This study was approved by the Joint Institutional Animal Use And Care Committee of the Hebrew University Veterinary Teaching Hospital (HUVTH) and the Kimron Veterinary Institute (KVI).

Experimental infection

Infectious larvae (L_3) of *S. lupi* were obtained from naturally-infected *O. sellatus* beetles collected from spirocercosis-endemic areas through dissection of the beetles.

Infectious larvae were harvested, divided into 10 aliquots of 40 larvae each and kept in saline at 4 °C pending inoculation (up to 3 days post harvesting). Dogs were randomly allocated to two 5-dog groups. In one group (study group), the dogs were treated with doramectin (Dectomax, Pfizer, Amboise, France, 400 µg/kg SC, 3 times, q30d). The 5 other dogs served as untreated controls. All dogs presented at least a single esophageal nodule of at least 1 cm in diameter and had positive fecal flotation for *S. lupi* eggs. One month after the last doramectin injection to the study group dogs, all dogs, including the control dogs, were orally challenged with 40 infectious *S. lupi* larvae as described previously (20, 21). A dog was considered to be infected when typical esophageal nodules were observed during endoscopy and *S. lupi* eggs were detected in its feces, or when *S. lupi* larvae or typical histopathological changes were found in the aorta on post mortem examination. At days 228 and 250 post inoculation (PI), for the doramectin-untreated and -treated dogs, respectively, a treatment protocol (doramectin, 400 µg/kg SC every 14 days, 6 times) was implemented for all the surviving infected dogs. The dogs were followed for 21 months post-inoculation (PI).

Fecal examination

Fecal samples (at least 30 g/sample, twice weekly) were collected from day 128 PI, homogenized, and three 5-gram aliquots per dog were analyzed per collection, using a sugar flotation method (17). The number of *S. lupi* eggs/gram feces for each sample was calculated as the mean egg number in the three aliquots.

Hematology and serum biochemistry

Samples for CBC and serum biochemistry analysis were collected from all dogs every 10-30 days by jugular venipuncture in potassium-EDTA and plain tubes. A CBC was performed within 30 minutes from collection using an automatic impedance hematology analyzer (Abacus, Diatron, Wien, Austria). The CBC included the white blood cell (WBC) count, red blood cell (RBC) count, hemoglobin concentration, hematocrit, (MCV), mean corpuscular hemoglobin, mean corpuscular hemoglobin concentration and platelet count. The differential WBC and the morphologic assessment of blood cells were performed manually by examination of modified Wright's-stained blood smears (Hema-Tek 2000 Slide Stainer, model 4488B, Bayer Corporation, Elkhart, IN, USA, Stain: Hematek stain pack; Modified Wright's Stain) by a single veterinary clinician. Samples for serum biochemistry analysis were allowed to clot at room temperature for 30 minutes, centrifuged, and sera were separated and stored at 4 °C pending analysis, generally within 24 hours from collection using a wet chemistry autoanalyzer (Kone lab, Kone, Espoo, Finland, at 37 °C). Serum biochemistry analysis included the following analytes: albumin, alanine aminotransferase, alkaline phosphatase, amylase, aspartate aminotransferase, bilirubin, calcium, chloride, cholesterol, creatine kinase, creatinine, γ -glutamyl transferase, glucose, lactate dehydrogenase,

phosphorus, potassium, sodium, total protein, triglycerides and urea. Globulin concentration was calculated by subtracting the albumin from the total protein concentration.

Endoscopy and pathology

Upper gastrointestinal endoscopy was performed monthly in each dog starting on day 128 PI, as described previously (20, 21). The diameter of esophageal lesions was calculated by recording the measurements on the endoscope. Necropsy and histopathology were performed on 2 dogs that died during the study.

Statistical analysis

The two groups (i.e., treated dogs and controls) were united for the purpose of statistical analysis. Due to the small study population, Friedman's non-parametric test was used to assess if there was a significant trend in the clinicopathologic analytes over time in repeated measures. Analytes in which a significant trend over time was observed in the above mentioned test, were analyzed post-hoc. Wilcoxon-signed-rank test, with Bonferroni's correction for α , was used for the post-hoc analysis of measures of analytes in consecutive samples. For all statistical tests, a P value < 0.05 was considered significant.

RESULTS

Experimental infection

Nine of 10 dogs became infected during the study period and only these nine dogs were included in the analyses. Infection was confirmed in 7 dogs (4 doramectin-treated and 3 untreated dogs) by observing esophageal nodules upon endoscopy and typical *S. lupi* eggs in fecal flotation. Two untreated dogs died suddenly on days 33 and 54 PI due to aortic aneurism rupture and subsequent hemothorax, and were confirmed with spirocercosis based on presence of *S. lupi* larvae and migration tracts in the aortic wall on post mortem gross examination and histopathology. One doramectin-treated dog did not become infected throughout the course of the study.

Fecal flotations

On fecal flotation, *S. lupi* eggs were first detected on days 128 to 241 PI in 7 dogs, while in one dog, feces remained negative throughout the study course. The maximal eggs per gram feces in the seven surviving infected dogs was between 12 to 550 during the course of the study.

Hematology and serum biochemistry

No morphological abnormalities were observed in the blood smears of all dogs throughout the study period. There were no significant differences ($P > 0.05$) in any laboratory measures between the study and the control groups throughout the study course. When the nine infected dogs were analyzed as a single group, there were no significant differences ($P > 0.05$) over time in repeated measures of the medians of the hematocrit, mean corpuscular hemoglobin, monocyte count, alanine aminotransferase, alkaline phosphatase (sALP), amylase, aspartate aminotransferase, creatine kinase (CK), γ -glutamyltransferase and lactate dehydrogenase (LDH) activity, total bilirubin, calcium, chloride, creatinine, globulin, glucose, phosphorus, potassium, sodium, total protein and urea concentration. Mostly, these analytes were within their reference intervals (RIs), or with minor deviations from RI in some dogs throughout the study period. There were significant differences ($P < 0.05$) over time in the RBC count, hemoglobin concentration, MCV, WBC count, neutrophil, lymphocyte and eosinophil counts and serum albumin concentration. MCV, WBC count, neutrophil, lymphocyte and eosinophil counts and serum albumin concentration. Nevertheless, with exception of the eosinophil count, there were no differences in these latter analytes between the different time points throughout the study period, and no consistent pattern of change could be observed over time. Furthermore, all these analytes remained within RI over time. Eosinophil counts increased significantly ($P < 0.017$) 14 days PI and both their median relative and absolute counts were above RI (17%; range, 7-36; RI: 0-10 and $2.19 \times 10^9/L$; range, 0.86-3.93; RI: 0.1-1.0 $\times 10^9/L$, respectively) (Figure 1).

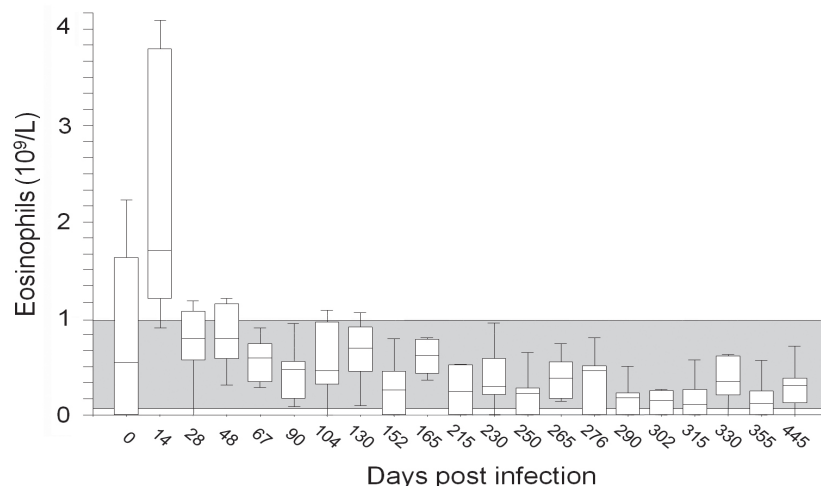


Figure 1

Absolute eosinophil counts in nine beagle dog experimentally-infected with *Spirocerca lupi* from infection up to formation of esophageal nodules, through treatment, until their complete resolution. The eosinophil count at 14 days post-infection was significantly ($P < 0.017$) higher compared to all their counts throughout the study course.

Their medians both decreased significantly ($P < 0.017$) at 4 weeks PI (10%; range, 0-14%; and $0.77 \times 10^9/L$; range 0.00-1.13, respectively) and were within RI. From that point onwards, both the relative and absolute eosinophil counts remained within RI throughout the study course (range, 3.8-9.3% and range, $0.026-0.776 \times 10^9/L$, respectively) that lasted 20 additional months. The eosinophil counts at 14 days PI were significantly higher compared to their counts at all time points throughout the study (Figure 1). No change in the eosinophil counts was observed during doramectin administration. There was no association between the eosinophil count and the time of appearance of the esophageal nodules. There was no correlation between eosinophil numbers and the number of *S. lupi* eggs shed in the feces.

Endoscopy

The first endoscopy, performed on day 121 PI, revealed esophageal nodules in all surviving untreated dogs. Nodules were initially observed in 2 doramectin-treated dogs on day 161 PI, and in 2 additional treated dogs on day 224 PI. One treated dog showed no endoscopic abnormalities throughout the study course. The esophageal nodules in all the infected dogs regressed, and eventually disappeared in response to doramectin therapy.

DISCUSSION

The clinicopathologic abnormalities in naturally-occurring canine spirocercosis have been reported previously in several retrospective studies that included dogs at different stages of the disease, some of which were advanced and chronic, and some presented esophageal neoplasia, and were thus variable (3-5, 9, 23). However, there is no such report of an experimental *S. lupi* infection. The present study is the first to follow the hematology and serum biochemistry of experimentally-*S. lupi*-infected dogs, from infection, through the formation of esophageal nodules, their regression following therapy and until their complete resolution. In contrast with past retrospective studies of naturally-occurring spirocercosis, the present study describes the clinicopathologic findings in a homogenous population of experimentally-infected, healthy beagle dogs, monitored periodically through hematology, serum biochemistry, endoscopy and fecal flotations. Thus, it provides an opportunity to assess presence of abnormalities in the early stages of spirocercosis, uncomplicated by secondary processes (e.g., esophageal neoplasia, pulmonary metastases and aspiration pneumonia) (3-5, 23), and concurrent, unrelated diseases (4). Although half of the dogs have been treated prophylactically with doramectin, and this has affected the time-lag from infection to appearance of esophageal nodules, 4/5 of these dogs were infected and did eventually develop an esophageal infection. Thus, it seems that uniting these two groups of dogs (i.e., infected treated dogs and infected, untreated dogs) for the purpose of the clinicopathologic followup is sound.

Previous retrospective studies of spirocercosis in dogs have

reported a mild to moderate normocytic normochromic anemia in 50% of the cases (3, 4) and in cases of advanced disease and esophageal neoplasia, a microcytic hypochromic anemia due to esophageal mass ulceration with subsequent melena (23). The normocytic normochromic anemia in the early disease stages was presumed to result from inflammation (i.e., anemia of chronic disease) (3, 4, 9). Presently, although significant changes in RBC, hemoglobin concentration and MCV over time were noted, no clear trend or pattern or significant differences in these analytes between repeated samples at different time-points and no deviations from RI were observed. Furthermore, there was no change over time of the hematocrit. Thus, it seems that anemia does not characterize early, uncomplicated canine spirocercosis.

Animals presented with advanced spirocercosis are also more likely to show leukocytosis, probably due to a high incidence of inflammation due to secondary complications (e.g., pneumonia and neoplasia) (3-5). In a study of spirocercosis-associated esophageal osteosarcomas, 82% of cases presented with leukocytosis, compared to 32% of patients with early spirocercosis only (3, 23). In another study of naturally-occurring spirocercosis, neutrophilic leukocytosis was significantly more common in infected dogs compared to *S. lupi*-negative controls. However, 14% of the dogs with spirocercosis in that study had other unrelated concurrent infectious diseases (e.g., leishmaniasis, dirofilariasis and monocytic ehrlichiosis) that likely affected the leukogram. In this study, there was a significant change over time in the total leukocyte, neutrophil, lymphocyte and eosinophil counts in repeated measures analysis, however, with exception of the eosinophil count, there were no consistent pattern or trend, or significant differences between time-points in these analytes, and they were within RI throughout the study period. In addition, in contrast with a previous report (3), monocytosis was not observed presently in any dog throughout the study period. Thus, it seems that a systemic inflammation, manifested by changes in total WBC and their differential count is uncommon in early, uncomplicated canine spirocercosis. Likely, the previously reported neutrophilic leukocytosis and monocytosis in naturally-occurring spirocercosis resulted from inflammation due to secondary, more chronic, disease-related processes and other concurrent unrelated infections. In a previous report, there was no correlation between leukocyte numbers and presence of spirocercosis-associated inflammatory conditions (e.g., pneumonia or spondylitis). The authors have thus concluded that the observed inflammatory response resulted from the esophageal nodule itself (3). The present results do not support this hypothesis, because there were no significant differences in the leukocyte and neutrophil counts between time points and no increases above RI throughout the study in spite of presence of endoscopy-confirmed esophageal nodules in all the surviving dogs.

The most significant hematologic change and abnormality presently was a mild to moderate, transient, absolute and relative eosinophilia at 14 days PI, which decreased significantly

two weeks later. Similarly, a transient eosinophilia has been described previously in experimental helminthic infections of dogs with *Dirofilaria immitis* (24) and *Angiostrongylus vasorum* (25) and in raccoon-dogs with *Trichinella nativa* (26). It has been proposed that eosinophilia associated with parasitism is more likely to occur when parasites are located in tissues rather than in the intestinal lumen (27). Thus, it is not surprising that in the present study, eosinophilia was observed shortly after infection, during *S. lupi* larval migration through the stomach wall into the wall of the gastric and gastroepiploic arteries, promoting a systemic eosinophilic response. However, it is currently unclear why this eosinophilia had such a short, transient nature, despite the continuous presence and tissue irritation caused by further larval migration, and later on, by presence of adult worms in the esophagus. The transient nature of eosinophilia, as well as similar observations in other experimental helminthic infections, raises several possible hypotheses of host-parasite interactions. A previous study that examined the histological changes in *S. lupi*-induced esophageal nodules has reported a small number of cases in which eosinophils predominated in the inflammatory infiltrate. The authors have hypothesized that this type of reaction could occur early in the course of the formation of esophageal nodules (28). If this is the case, an early systemic eosinophilic reaction probably precedes a local esophageal eosinophilic reaction within the nodule. The relatively early decrease of the eosinophil counts PI might be related to *S. lupi* evasion from the host's defense mechanisms, through antigenic changes in the parasite's cuticle, suppression of the immune system by secretion of factors that mediate the host's immune response or altering the Th-2 response of their hosts through the induction of immunoregulatory cytokines such as interleukin-10 (IL-10) (29). It has been shown that expulsion of certain isolates of *Trichuris muris* from C57BL/6 mice is associated with the development of a Th-2 response; while in contrast, the survival of another isolate in C57BL/6 mice correlates with a reduced Th-2 and increased Th-1 responses, and that regulation of T cell functions facilitates the latter isolate's survival within mice (30-32). Whether *S. lupi* evokes similar immune reactions and whether such mechanisms are responsible for the transient nature of the eosinophilia as observed in the current study, warrant further study.

The transient nature of this eosinophilia, as well as the fact that it was only mild to moderate, along with the fact that the dogs did not present clinical abnormalities when eosinophilia was present, renders this finding not useful for diagnostic purposes in clinical settings. The absence of eosinophilia in the more advanced stages of this experimental disease and the lack of association between the number of *S. lupi* eggs shed in the feces or the time of formation of esophageal nodules also support previous observations in retrospective studies in naturally-occurring spirocercosis. Eosinophilia was uncommon in one study, and was present in 5% of infected dogs in another (3, 4).

There are no typical reported biochemical changes in dogs with

early spirocercosis other than mildly increased serum creatine kinase activity, reported in 54% of dogs in one study (3, 5). Once neoplastic transformation has occurred, however, increased sALP, CK, amylase and LDH activity have been noted (23). No blood chemistry or hematologic differences were observed between native Kenyan dogs with or without spirocercosis (33). In another retrospective study, hyperproteinemia and increased sALP were present in 33% and 23% of 56 *S. lupi*-infected dogs, respectively (4). The present results suggest that serum biochemistry abnormalities in the early stages of spirocercosis are mostly absent, or minimal, as the medians of all analytes measured presently were within RI throughout the study period. Although there were differences over time in repeated measure analysis of albumin concentration, there were no significant differences in its concentrations between consecutive time-points throughout the study period. No changes over time were observed in total protein and globulin concentration in the present study, in contrast to the above mentioned findings (4). The differences between our negative results and the serum biochemistry abnormalities observed in previous retrospective studies of naturally-occurring spirocercosis are likely because in the latter, dogs were ill and mostly presented with an advanced disease. In contrast, in the present study, the dogs had no spirocercosis-related clinical signs. Additionally, the disease was in an early stage and was treated early with doramectin when the esophageal nodules' size was limited and this treatment resulted in complete resolution of the disease. Probably, in the naturally-occurring cases, stress, secondary complications and presence of other concurrent diseases were responsible for most reported biochemical abnormalities. Chronic illness often leads to cortisol release and is sometimes associated with increased sALP activity in dogs (34).

The present study has several limitations; First, it included only 10 dogs, of which one did not become infected throughout the study course, and was thus excluded from the analyses, while two dogs died early due to ruptured aortic aneurysms. Thus, only seven dogs were followed from infection up to complete resolution of the esophageal nodules. The relatively small number of dogs limited the strength of the statistical analyses. Secondly, the dogs were divided to two groups, one of which was treated prophylactically with doramectin. For the purpose of the present analysis of the clinicopathologic analytes, both groups were combined. This could be done because four of five dogs in the doramectin-treatment group did develop infection and esophageal nodules, although their responses to infection might have been blunted by treatment. Nevertheless, all dogs were sampled periodically over a very long period, up to full recovery, and no differences between groups in all analytes measured throughout the study were observed. Thus, we believe that the results provide an adequate picture of the hematologic and serum biochemistry analyte levels in this experimental infection.

In conclusion, the hematologic and serum biochemistry changes in this experimental infection of dogs with *S. lupi*, from infection, through formation of esophageal nodules, and

during treatment until complete resolution of the disease were minimal. The only significant change was a transient mild to moderate eosinophilia 14 days PI, that subsided within the subsequent 14 days, and that likely cannot aid in the diagnosis of spirocercosis in its early stages in a clinical setting. There were no associations between any of the analytes measured in the study and the time of formation of esophageal nodules or number of the nematode eggs shed in the feces.

REFERENCES

- Bailey, W.S. *Spirocerca lupi*: a continuing inquiry. J. Parasitol. 58:3-22, 1972.
- Soulsby, E. J. L. Helminths, Arthropods and Protozoa of Domesticated Animals. Bailliere-Tindall, London, pp. 291-294, 1986.
- Mazaki-Tovi, M., Baneth, G., Aroch, I., Harrus, S., Kass, P., Ben-Ari, T., Zur, G., Aizenberg, I., Bark, H. and Lavy, E. Canine spirocercosis: clinical, diagnostic, pathologic, and epidemiologic characteristics. Vet. Parasitol. 107, 235-250, 2002.
- Mylonakis, M. E., Rallis T., Koutinas, A. F., Leontides, L.S., Patsikas, M., Florou, M., Papadopoulos, E. and Fytianou, A. Clinical signs and clinicopathologic abnormalities in dogs with clinical spirocercosis: 39 cases (1996-2004). J. Am. Vet. Med. Assoc. 228:1063-1067, 2006.
- van der Merwe, L. L., Kirberger, R. M., Clift, S., Williams, M., Keller, N. and Naidoo, V. *Spirocerca lupi* infection in the dog: a review. Vet. J. 176:294-309, 2008.
- Fox, S.M., Burns, J. and Hawkins, J. Spirocercosis in dogs. Comp. Contin. Edu. Pract. Vet. 10:807-822, 1988.
- Urquhart, G. M., Armour, J., Duncan, J. L., Jennings, F. W. and Dunn, A. M. Veterinary Parasitology. Blackwell Science, Glasgow, pp. Vet. Parasitol. 79-81, 1996.
- Dvir, E., Kirberger, R. M. and Malleczek, D. Radiographic and computed tomographic and clinical presentation of spirocercosis in the dog. Vet. Radiol. Ultrasound 42:119-129, 2001.
- Dvir, E., Kirberger, R.M., Mukorera, V., van der Merwe, L.L and Clift, S.J. Clinical differentiation between dogs with benign and malignant spirocercosis. Vet. Parasitol. 155:80-88, 2008.
- Chhabra, R.C. Symptoms and pathogenesis of spirocercosis in dogs. Ind. Vet. J. 50, 551-554, 1973.
- Ndiritu, C.G.; Pathogenesis and lesions of canine spirocercosis. Mod. Vet. Pract. 57:924-931, 1976.
- Ivoghli, B. Fatal aortic aneurysm and rupture caused by *Spirocerca lupi* in a dog. J. Am. Vet. Med Assoc. 170:834, 1977.
- Dvir, E., Perl, S., Loeb, E., Shklar-Hirsch, S., Chai, O., Mazaki-Tovi, M., Aroch, I. and Shamir, M. H. Spinal intramedullary aberrant *Spirocerca lupi* migration in 3 dogs. J. Vet. Intern. Med. 21:860-864, 2007.
- Harrus, S., Harmelin, A., Markovics, A. and Bark, H. *Spirocerca lupi* infection in the dog: aberrant migration. J. Am. Anim. Hosp. Assoc. 32:125-130, 1996.
- Klainbart, S., Mazaki-Tovi, M., Auerbach, N., Aizenberg, I., Bruchim, Y., Dank, G., Lavy, E., Aroch, I. and Harrus S. Spirocercosis-associated pyothorax in dogs. Vet. J. 173:209-214, 2007.
- Gal, A., Klainbart, S., Aizenberg, Z. and Baneth, G. Aortic thromboembolism associated with *Spirocerca lupi* infection. Vet. Parasitol. 130:331-335, 2005.
- Markovics, A. and Medinski, B. Improved diagnosis of low intensity *Spirocerca lupi* infection by the sugar flotation method. J. Vet. Diag. Investig. 8:400-401, 1996.
- Traversa, D., Costanzo, F., Iorio R., Aroch I. and Lavy E. Mitochondrial cytochrome c oxidase subunit 1 (cox1) gene sequence of *Spirocerca lupi* (Nematoda, Spirurida): avenues for potential implications. Vet. Parasitol. 146:263-270, 2007.
- Traversa D., Avolio S., Modrý D., Otranto D., Iorio R., Aroch I., Cringoli G., Milillo P., Albrechtová K., Mihalca A. D. and Lavy, E. Copromicroscopic and molecular assays for the detection of cancer-causing parasitic nematode *Spirocerca lupi*. Vet. Parasitol. 157:108-116, 2008.
- Berry, W.L. *Spirocerca lupi* esophageal granulomas in 7 dogs: resolution after treatment with doramectin. J. Vet. Intern. Med. 14:609-612, 2000.
- Lavy, E., Harrus, S., Mazaki-Tovi, M., Bark, H., Markovics, A., Hagag, A., Aizenberg Z. and Aroch, I. *Spirocerca lupi* in dogs: prophylactic effect of doramectin. Res. Vet. Sci. 75:217-222, 2003.
- Lavy, E., Aroch, I., Bark, H., Markovics, A., Aizenberg, I., Mazaki-Tovi, M., Hagag, A. and Harrus, S. Evaluation of doramectin for the treatment of experimental canine spirocercosis. Vet. Parasitol. 109:65-73, 2002.
- Ranen, E., Lavy, E., Aizenberg, I., Perl, S. and Harrus, S. Spirocercosis-associated esophageal sarcomas in dogs. A retrospective study of 17 cases (1997–2003). Vet. Parasitol. 119:209-221, 2004.
- Rawlings, C. A. Clinical laboratory evaluations of seven heartworm infected beagles: during disease development and following treatment. Cornell Vet. 72:49-56, 1982.
- Cury, M.C., Lima, W. S., Guimarães, M.P. and Carvalho, M.G. Hematological and coagulation profiles in dogs experimentally infected with *Angiostrongylus vasorum* (Baillet, 1866). Vet. Parasitol. 104:139-149, 2002.
- Näreaho, A., Sankari, S., Mikkonen, T., Oivanen, L. and Sukura, A. Clinical features of experimental trichinellosis in the raccoon dog (*Nyctereutes procyonoides*). Vet. Parasitol. 91:79-91, 2000.
- Young, K. M. and Meadows, R. L. Eosinophils and their disorders. In: Weiss, D.J. and Waldrop, K.J. (Eds): Schalm's Veterinary Hematology, 6th Edition. Blackwell Publishing, Ames, pp. 281-89, 2010.
- Dvir E, Clift SJ, Williams MC. Proposed histological progression of the *Spirocerca lupi*-induced oesophageal lesion in dogs. Vet. Parasitol. 168:71-77, 2010.
- Figueiredo, A.S., Höfer, T., Klotz C., Sers, C., Hartmann, S., Lucius, R. and Hammerstein P. Modelling and simulating

- interleukin-10 production and regulation by macrophages after stimulation with an immunomodulator of parasitic nematodes. FEBS J. 276:3454-3469, 2009.
30. Johnston, C. E., Bradley, J. E., Behnke, J. M., Matthews, K. R. and Else, K. J. Isolates of *Trichuris muris* elicit different adaptive immune responses in their murine host. Parasite Immunol. 27:69-78, 2005.
 31. Bellaby, T., Robinson, K. and Wakelin, D. Induction of differential T helper-cell responses in mice infected with variants of the parasitic nematode *Trichuris muris*. Infect. Immun. 64:791-795, 1996.
 32. D'Elia, R., Behnke, J.M., Bradley, J.E. and Else, K.J. Regulatory T cells: a role in the control of helminth-driven intestinal pathology and worm survival. J. Immunol. 182:2340-2348, 2009.
 33. Brodey, R.S., Thompson, R.G., Sayer, P.D. and Eugster, B. *Spirocerca lupi* infection in dogs in Kenya. Vet. Parasitol. 3:49-59, 1977.
 34. Hoffmann, W. E. and Solter, P.F. Diagnostic enzymology of domestic animals. In: Kaneko, J, J., Harvey, J.W. and Bruss, M.L. (Eds.): Clinical Biochemistry of domestic
 35. Animals, 6th Edition. Academic Press, San Diego, pp. 351-378, 2008.