

Hypertrophic Osteopathy in a Three-Year-Old Quarter Horse Mare

Bayless, R., Almes, K., Choudhary, S., Beard, W., Garcia, E. and Biller, D.

Kansas State University College of Veterinary Medicine, Manhattan, KS.

Kansas State Veterinary Diagnostic Laboratory-Department of Diagnostic Medicine/Pathobiology (Almes, Choudhary) and Department of Clinical Sciences (Beard, Biller, Garcia).

* **Corresponding Author:** Rosemary Bayless, 2150 Georgetown Road, Lexington, KY 40511. Email: RBaylessDVM@gmail.com

ABSTRACT

A three-year-old female intact Quarter Horse with a history of bony enlargement of the mandible and both radii, third metacarpal bones, and third metatarsal bones was donated to a university teaching hospital for euthanasia. Mild weight loss of several months duration and a previous wound near the site of the mandibular swelling were also reported. There were no significant findings on physical examination except for the firm enlargement of the left mandible and distal limbs. She was non-reactive to palpation of the swellings and did not appear lame at the walk, although a complete lameness examination was not performed. Radiographs revealed bilaterally thickened cortices of the third metacarpal and metatarsal bones and periosteal proliferation along the ventral portion of the left mandible immediately caudal to the mandibular symphysis. Thoracic radiographs were unremarkable. On post-mortem exam, the only gross abnormalities noted were diffuse fibrous adhesions between the pericardium and the epicardial surface of the heart and bilaterally symmetrical firm bony proliferation hemi-circumferentially around the distal radii, along the length of the third metacarpal and metatarsal bones, and on the rostral left mandible. Histopathology of the heart revealed fibrous tissue deposition along the epicardial surface with small multifocal infiltrates of lymphocytes and plasma cells. Microscopic examination of the affected mandible and third metatarsal bone were consistent with periosteal proliferation consisting of bony and fibrous tissues. Hypertrophic osteopathy is uncommonly diagnosed in horses and has been most commonly described secondary to intrathoracic lesions such as infectious or neoplastic processes. In this case, the development of periosteal proliferation may have been a consequence of a previous episode of pericarditis.

Keywords: Hypertrophic Osteopathy, Pericarditis, Quarter Horse, Equine.

INTRODUCTION

Hypertrophic osteopathy has been reported in multiple species, including humans, dogs, and horses, but is considered uncommon in equine patients. Diagnosis of hypertrophic osteopathy in horses is typically based on physical examination findings of bony enlargement in multiple distal limbs and radiographic evidence of diaphyseal and/or metaphyseal periosteal proliferation. Lesions are most commonly described on the metacarpal and metatarsal bones, phalanges, and distal radius and tibia. There have also been reports of bony proliferation involving the mandible, maxilla, and nasal

bones, either alone or in combination with distal limb long bones (1, 2). The inciting cause for the new bone growth is not always identified, but hypertrophic osteopathy has been associated with intrathoracic pathology, such as neoplasia or granulomatous disease, and less commonly, lesions involving other organ systems, such as ovarian granulosa cell tumors and gastric squamous cell carcinoma (2-4).

CLINICAL CASE REPORT

A three-year-old female intact Quarter Horse was donated to the Veterinary Health Center at Kansas State University

(KSU-VHC) with a history of bony enlargement of the left side of the mandible and both radii, third metacarpal bones, and third metatarsal bones. A referring veterinarian had examined the horse two months previously for an old wound on the left mandibular body and noted the bilateral metacarpal and metatarsal enlargement. The owners reported no recent changes in the appearance of the horse's limbs. Since the initial evaluation by the referring veterinarian, the horse had lost weight but the bony proliferation appeared unchanged.

On presentation, the patient was quiet and had normal vital parameters except for mild tachypnea (Temperature: 36.7°C, Pulse: 40 bpm, Respiration: 28 bpm). Both metacarpal and metatarsal regions were noticeably enlarged, as were the distal radii (Figures 1a, 1b) and the left side of the mandible. There was no longer a visible skin wound in the area of the mandibular enlargement. She was not sensitive to palpation of the bony swellings on her limbs or mandible and did not appear to be lame, although a full lameness examination was not performed. No abnormalities were noted during a rectal examination.

Radiographs by the referring veterinarian showed thickened cortices with palisading bony proliferation. Upon presentation to KSU-VHC, skull and thoracic radiographs were taken to evaluate the mandibular osseous changes and check for primary intrathoracic disease. The dorsoventral view of the skull showed thickening of the rostral left hemimandible just caudal to the mandibular symphysis (Figure 2a). The borders of the new bone were smooth, and there was minimal soft tissue swelling. On the lateral view, there was a mineral opacity bulge ventral to the mesial root of the mandibular third premolar. A lucent tract appeared to extend from the alveolar bone immediately adjacent to the tooth down to just beneath the skin surface (Figure 2b).

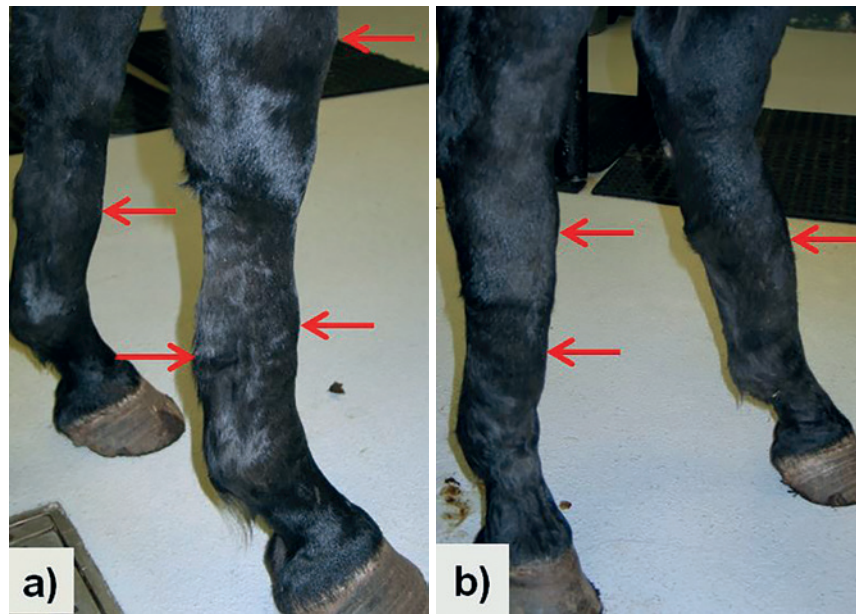


Figure 1: Photographs upon presentation of a) distal front limbs and b) distal hind limbs showing bilateral gross bony enlargement of metacarpal and metatarsal diaphyses and distal radii (arrows).

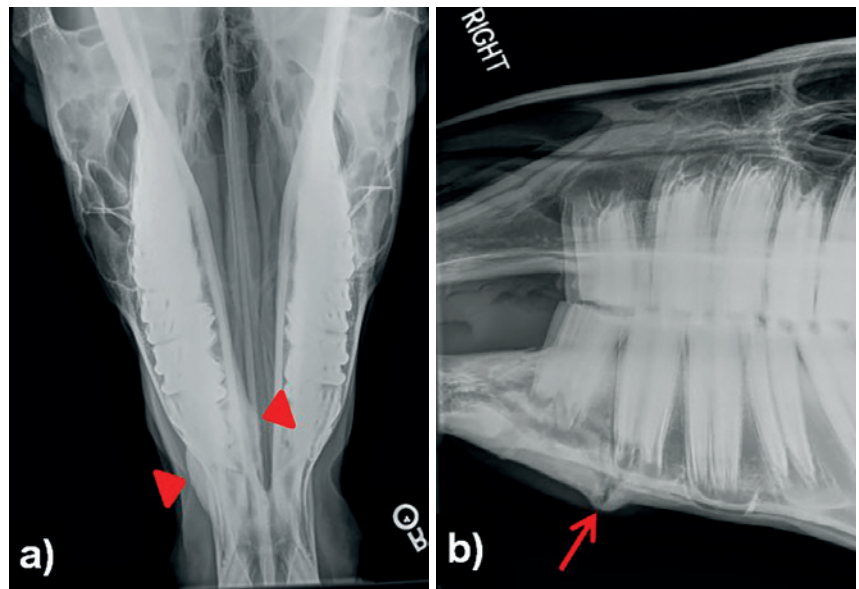


Figure 2: Radiographs of the skull a) dorsoventral view (arrowheads indicate focal thickening of left hemimandible) and b) lateral view (arrow indicates bony swelling containing lucent tract)

No abnormalities were noted on the thoracic films, and the lower respiratory tract appeared to be within normal limits. Humane euthanasia was performed as was planned at time of donation, and no further diagnostics were performed prior to death. A post-mortem examination was performed several hours after euthanasia.

GROSS LESIONS

The pericardium was diffusely adhered to the epicardial surface of the heart, and the two layers could not be separated from one another without tearing the fibrous tissue. There was no significant fluid contained in the pericardial sac. After removal of the pericardial tissue, plaques of fibrous tissue remained on the surface of the heart (Figure 3). No exten-

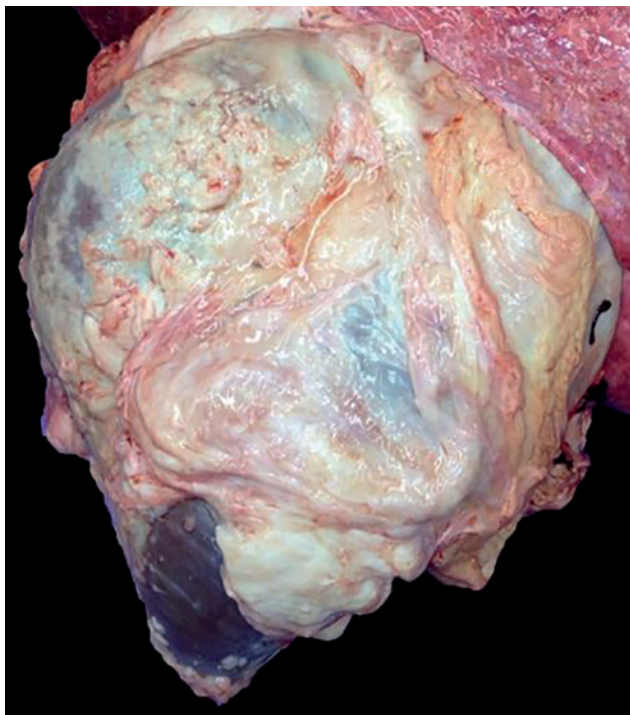


Figure 3: Heart with pericardial tissue removed demonstrating diffuse fibrous tissue adhered to the epicardium.

sion of fibrous tissue or signs of inflammation were observed grossly in the myocardium or endocardium.

There was marked hemi-circumferential firm expansion of both distal radii, both third metacarpal diaphyses and both third metatarsal diaphyses. The left hind limb was removed immediately distal to the tarsometatarsal joint, and a cross-section was taken from around the level of the middle one-third of the metatarsal diaphysis. This cross-section demonstrated extensive bony proliferation as well as exuberant fibrous tissue which contained small islands of mineralized bone. The right hind limb was removed proximal to the tarsus for radiographic evaluation.

The rostral left hemimandible was significantly enlarged when compared to the right hemimandible; this marked asymmetry was emphasized when the skin and soft tissues were removed (Figure 4a). On cross-section of the mandible around the level of the second premolar, the extent of new bony proliferation and partial obliteration of distinct corticomedullary architecture were evident (Figure 4b).

No abnormalities were noted on gross examination of the trachea, lungs, great vessels, liver, spleen, kidneys, adrenal glands, gastrointestinal tract, uterus, or ovaries.

MICROSCOPIC LESIONS

Histopathology of the epicardium and superficial myocardium revealed a layer of fibrous tissue tightly adhered to the epicardial surface. This fibrous tissue varied from densely-to loosely-arranged and contained multifocal infiltrates com-

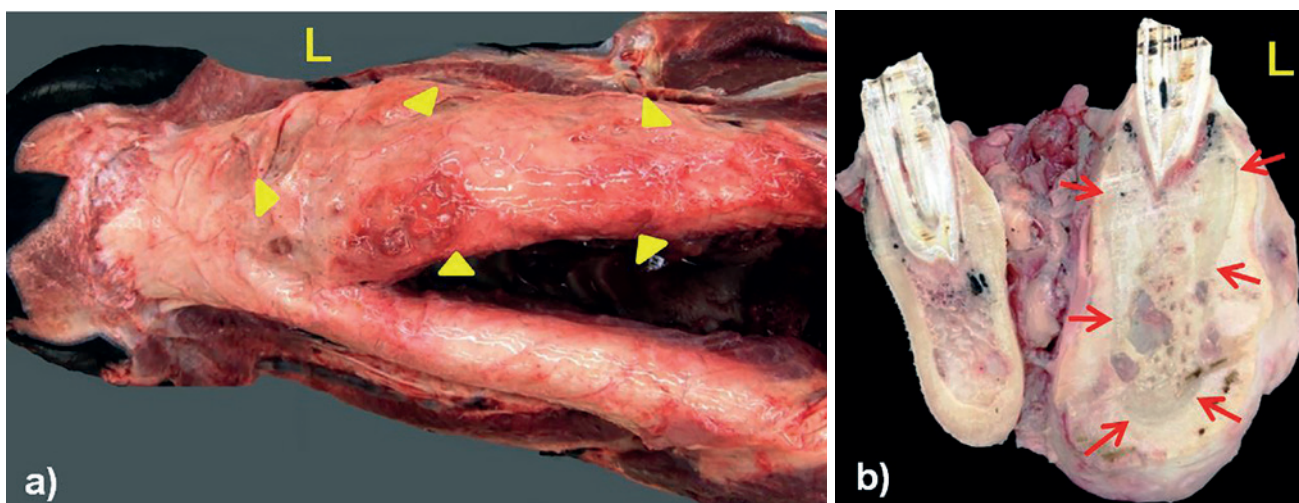


Figure 4: Bony proliferation of left hemimandible a) ventral surface of mandible with skin and soft tissues removed (arrowheads indicate approximate margins of bony enlargement) and b) cross-section of mandible at approximately the level of the second premolar (arrows indicate original periosteal margin)

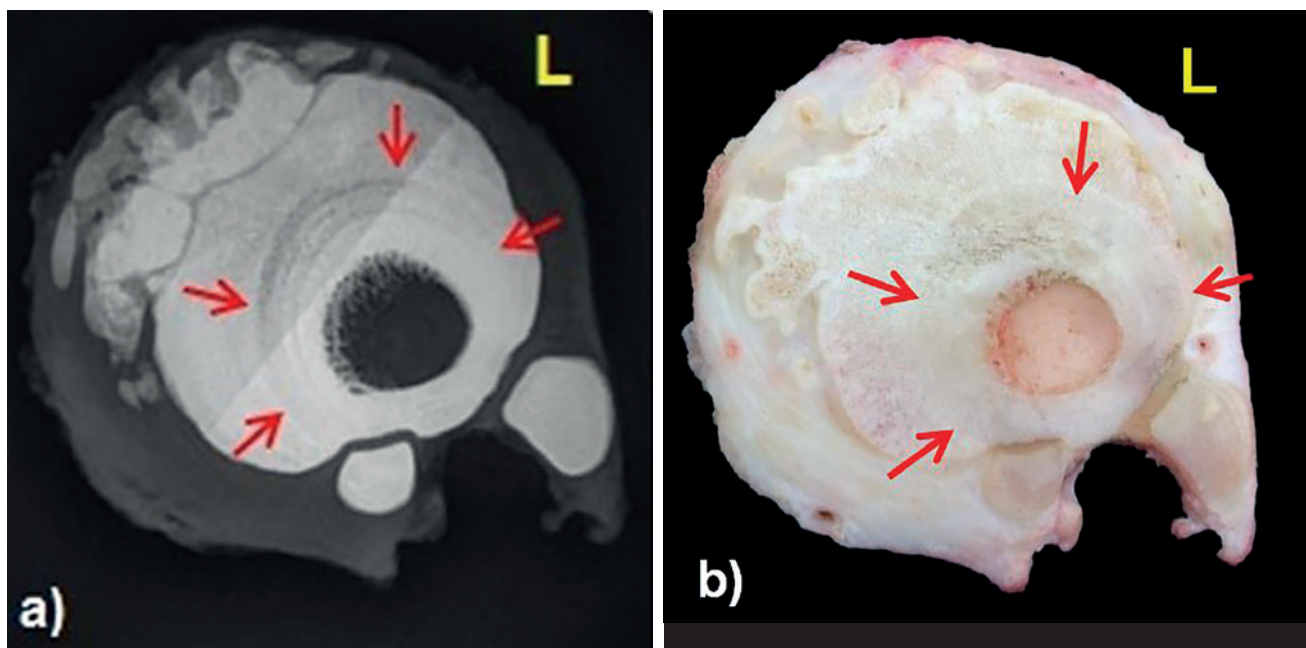


Figure 5: Left hind metatarsal cross section a) radiograph and b) photograph (arrows indicate normal periosteal margin)

posed of small to moderate numbers of lymphocytes and plasma cells. A diagnosis of lymphoplasmacytic epicardial fibrosis was made based on these results along with the gross findings.

Microscopic examinations of the left hind metatarsal cross-section and mandibular enlargement were performed following decalcification. Portions of the new bone formation on the dorsal surface of the third metatarsal bone formed projections of trabecular bone surrounded by dense fibrous tissue. There were voids within the proliferative bone that resembled medullary-like areas that contained adipose tissue but no evidence of myeloproliferative tissue.

The histopathology of the mandibular mass showed three distinct layers composed of original compact cortical bone of the mandible, proliferative trabecular bone, and dense fibrous tissue. The new trabecular bone on the mandible was similar to the new metatarsal bone but appeared slightly more organized. The histological appearance of tissue sections from the distal limb and mandibular bony lesions were consistent with a morphologic diagnosis of moderate, multifocal periosteal hyperostosis.

FURTHER DIAGNOSTICS

Radiographs of the right hind distal limb and left hind metatarsal cross-section were obtained post-mortem. The meta-

tarsal cross-section radiograph (Figure 5a) closely resembled the gross appearance of the cut section (Figure 5b) and was characterized by significant smooth hemi-circumferential periosteal new bone formation on the medial, dorsal, and lateral aspects of the third metatarsal bone. The dorsal surface of the bony proliferation featured irregularly-margined mineral opacities separated from the main portion of bone by thin curvilinear lucencies. There was also thickening of the soft tissue surrounding the metatarsal bones, especially on the medial side of the leg, and the soft tissue itself had irregular edges. The second and fourth metatarsal bones appeared within normal limits.

The irregular bony margins of the right hind metatarsi can be visualized on the lateromedial (lateral) radiograph (Figure 6a), and periosteal proliferation was also evident on the dorsoplantar view (Figure 6b). The smooth new bone formation appeared to stretch from immediately distal to the tarsometatarsal joint to the distal metaphyseal region of the third metatarsal bone, but there was no radiographic evidence of articular involvement. On the lateral and dorsoplantar views, the dorsal, medial, and lateral cortices were markedly thickened, and the medullary cavity appeared subjectively narrowed in the mid-diaphyseal region. The majority of the overlying irregularly-margined mineral opacity was centered on the proximal two-thirds of the third metatarsal.

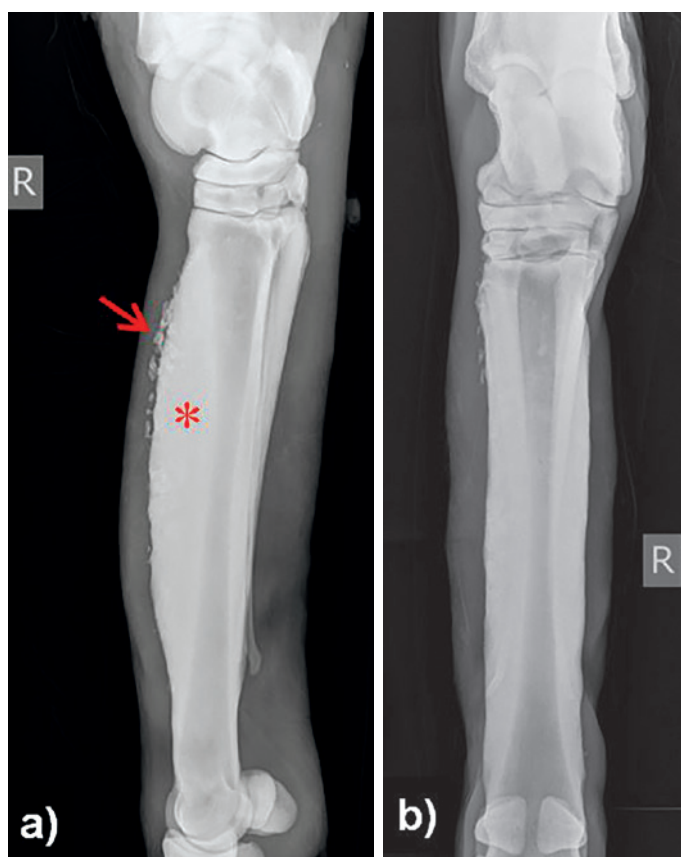


Figure 6: Radiograph of right hind metatarsal; a) lateromedial view, b) dorsoplantar view (asterisk shows cortical thickening, arrow indicates irregularly margined periosteal proliferation).

DISCUSSION

This report describes a case in which a presumptive ante-mortem diagnosis of hypertrophic osteopathy was made in a horse based on history, physical examination findings, and skull and distal limb radiographs. The gross and histopathology lesions from the post-mortem examination were also consistent with hypertrophic osteopathy. Since hypertrophic osteopathy is often secondary to an intrathoracic lesion, the fibrous pericarditis appears to be the inciting cause in this horse.

The horse was originally examined by the referring veterinarian for mandibular swelling, and the duration of distal limb bony enlargement prior to presentation was not clear. The patient also had no reported history of clinical signs consistent with pericarditis, such as pyrexia, depression, or inappetence, so the chronological relationship to the development of the bony proliferation, and thus the significance of this lesion as a potential etiology for her hypertrophic osteopathy, was unknown. The weight loss observed by the

owners may have been associated with the hypertrophic osteopathy disease process or may have occurred independently due to a number of different factors, including diet, exercise, and gastrointestinal parasitism.

The bilateral and symmetrical nature of the distal limb periosteal proliferation was consistent with descriptions of typical hypertrophic osteopathy lesions. The asymmetry of the mandibular lesion was uncharacteristic of hypertrophic osteopathy, suggesting a separate pathologic process from the periosteal proliferation observed in the distal limbs. The history of a wound on the mandible corresponding to the area of bony swelling and radiographic evidence of a previously draining tract presented another possible etiology for the mandibular new bone production: local inflammatory response to trauma.

The pathophysiology of hypertrophic osteopathy is not completely understood. Theories generally involve an initial increase in blood flow to the distal limbs via vasodilation and subsequent proliferation of connective tissue leading to bone deposition (1, 5). Proposed mechanisms of increased circulation include increased parasympathetic tone due to vagal nerve stimulation, a hypothesis that has been supported by the clinical improvement in some human patients after vagotomy or infusion of local anesthetic next to the vagal nerve (5). Others suggest that pulmonary vascular shunting arising from lung pathology results in increased amounts of vasoactive substances, such as growth factors, that would otherwise be inactivated or removed in pulmonary capillaries. The possible role of hormonal factors has also been investigated, but estrogen levels in horses have generally been within normal limits in the limited cases in which they were measured (2).

The results of some studies suggest that equine hypertrophic osteopathy tends to be diagnosed more commonly in young adult males, but horses of varying age and gender appear susceptible and small sample sizes of published data pose risk for over-interpretation of possible signalment risk factors. Affected horses commonly present with histories of weight loss and may also show other signs of systemic disease, such as fever, coughing, or dyspnea. The bony swellings, which are typically symmetrical and present on all limbs, can range from warm and sensitive to palpation, suggestive of active inflammation, to cool and apparently painless (2). Lameness and reduced range of motion in affected limbs have been reported but are not consistent in all cases (1, 6).

Radiographs of the affected limbs typically display pali-

sading new periosteal bone formation, but more chronic lesions may have smooth margins. The diaphyses and metaphyses of distal limb long bones are the most common locations for bony proliferation, as was observed in this horse. Although lesions often extend to the metaphyses, articular surfaces are generally not involved. When bony swellings associated with the skull are present, they also may have either smooth or spiculated edges (1). The use of nuclear scintigraphy to confirm increased bone turnover in the areas around palpable lesions has also been described (7).

Though additional diagnostics beyond physical examination and radiographs may not be necessary for diagnosis of hypertrophic osteopathy, they can provide information about the possible etiology of the periosteal proliferations. Clinical pathology results are often nonspecific, but the most commonly reported findings include a leukocytosis characterized by mature neutrophilia and hyperfibrinogenemia. Thoracic radiographs, bronchoalveolar lavage, transtracheal wash, and airway endoscopy may reveal a source of pulmonary disease contributing to the bony proliferation. Abdominal ultrasound, abdominocentesis, and rectal palpation can be used to assess the likelihood of a peritoneal lesion or an ovarian tumor (1, 2). The lack of significant findings on thoracic radiographs and rectal palpation in this horse was consistent with the absence of gross lesions observed in the lungs, peritoneal cavity, and retroperitoneal space during the post-mortem examination.

The prognosis of patients with hypertrophic osteopathy often depends on the underlying condition, if any can be identified, responsible for the bony proliferation. If the primary cause can be addressed, the bony enlargements may regress, as has occurred in some cases of hypertrophic osteopathy thought to be associated with inflammatory or infectious disease (2, 8). Many horses are euthanized soon after diagnosis without attempting treatment, while other non-survivors are euthanized several months later after a deterioration of their condition. In horses for which a primary condition was not determined, resolution was sometimes seen following symptomatic therapy with non-steroidal anti-inflammatory drugs (2).

While there was no history suggestive of clinical pericarditis in this horse, the fibrous tissue adhering to the pericardium to the epicardium is indicative of previous inflammation. A review of the literature reveals one other report of equine hypertrophic osteopathy attributed to fibrous pericarditis and

epicarditis. A Saddlebred gelding had a history of intermittent pyrexia prior to development of distal limb bony enlargement but was afebrile with normal thoracic auscultation when he was donated to another teaching hospital. As was the case for the Quarter Horse mare described in this report, no cardiac abnormalities were noted on thoracic radiographs of the gelding prior to euthanasia, but gross evidence of fibrous pericarditis and epicarditis was observed during the post-mortem exam (7).

Although hypertrophic osteopathy is uncommon in horses and generally associated with a primary condition, it should be considered as a differential for bilaterally symmetric bony enlargement affecting multiple limbs even in the absence of clinical signs or ante-mortem diagnostic findings of clinical disease affecting other body systems.

ACKNOWLEDGEMENTS:

Special thanks for assistance and images: Dr. Kelli Almes, DVM, DACVP; Dr. Shambhunath Choudhary, DVM; PhD., KSU-VHC Radiology Service, Kansas State Veterinary Diagnostic Laboratory-Histopathology Section; Dr. Sarah Keiser Czarnick, DVM.

REFERENCES:

- Enright, K., Tobin, E. and Katz, L.M.: A review of 14 cases of hypertrophic osteopathy (Marie's disease) in horses in the Republic of Ireland. *Equine Vet. Edu.* 23:224-230, 2011.
- Mair, T.S., Dyson, S.J., Fraser, J.A., Edwards, G.B., Hillyer, M.H., and Love, S. Hypertrophic osteopathy (Marie's disease) in Equidae: a review of twenty-four cases. *Equine Vet. J.* 28:256-262, 1996.
- Packer, M. and McKane, S. Granulosa theca cell tumor in a mare causing hypertrophic osteopathy. *Equine Vet. Edu.* 24:351-356, 2012.
- Schleining, J.A. and Voss, E.D. Hypertrophic osteopathy secondary to gastric squamous cell carcinoma in a horse. *Equine Vet. Edu.* 16:304-307, 2004.
- Mair, T.S. and Tucker, R.L. Hypertrophic osteopathy (Marie's disease) in horses. *Equine Vet. Edu.* 16:308-311, 2004.
- Lavoie, J-P, Carlson, G., and George, L. Hypertrophic osteopathy in three horses and a pony. *J. Am. Vet. Med. A.* 201:1900-1904, 1992.
- Long, M.T., Foreman, J.H., Wallig, M.A., Chambers, M.D., Losonsky, J.M., Muhlbauer, M.C. Hypertrophic osteopathy characterized by nuclear scintigraphy in a horse. *Vet. Radiol. Ultrasoun.* 34:289-294, 1993.
- Chaffin, M.K., Ruoff, W.W., Schmitz, G.K., Carter, G.K., Morris, E.L., and Steyn, P. Regression of hypertrophic osteopathy in a filly following successful management of an intrathoracic abscess. *22:62-65*, 1990.